

Anatomical Variations of Frontal Sinus Among Ethnic Populations Living in Karachi



**DR QURATULAIN JAVAID
MBBS, PGD-BIOETHICS**

**BAHRIA UNIVERSITY ISLAMABAD
PAKISTAN
SEPTEMBER 2019**

**ANATOMICAL VARIATIONS OF FRONTAL
SINUS AMONG ETHNIC POPULATIONS
LIVING IN KARACHI**

BY

**DR QURATULAIN JAVAID
MBBS, PGD-BIOETHICS**

**A thesis presented to Bahria University, Islamabad
In partial fulfillment of the requirement for the degree of
Master of Philosophy in Anatomy**



**DEPARTMENT OF ANATOMY
BAHRIA UNIVERSITY MEDICAL &
DENTAL COLLEGE**

2019

BAHRIA UNIVERSITY ISLAMABAD
APPROVAL SHEET
SUBMISSION OF HIGHER RESEARCH DEGREE THESIS

Candidate's Name: Dr. Quratulain Javaid

Discipline: MPhil Anatomy

Faculty/Department: Anatomy

I hereby certify that the above candidate's work including the thesis has been completed to my satisfaction and that the thesis is in a format of an editorial standard recognized by the faculty / department as appropriate for examination.

Signature: 

Principal Supervisor: Prof. Dr. Ambreen Usmani

Date: 23rd September 2019

The undersigned signifies that:

1. The candidate presented at a pre-completion seminar, an overview and synthesis of major findings of the thesis, and that the research is of a standard and extent appropriate for submission as a thesis.
2. I have checked the candidate's thesis and its scope, format and editorial standards are recognized by the faculty / department as appropriate.

Signature: 

Head of Department: Prof. Dr. Ambreen Usmani

Date: 23rd September 2019

Copyright © 2019, Dr Quratulain Javaid
All rights reserved.

AUTHOR'S DECLARATION

I, Dr. Quratulain Javaid hereby state that my MPhil thesis titled “Anatomical Variations of Frontal Sinus Among Ethnic Populations Living in Karachi” is my own work and has not been submitted previously by me for taking any degree from this university, **The Bahria University** or anywhere else in the country/world. At any time if my statement is found to be incorrect even after my graduation the university has the right to withdraw/cancel my MPhil degree.

Name of student: Dr. Quratulain Javaid

Date: 23rd September 2019

THESIS COMPLETION CERTIFICATE

Student's Name: Dr. Quratulain Javaid


Registration No: 55007

Program of Study: MPhil Anatomy

Thesis Title: Anatomical Variations of Frontal Sinus Among Ethnic Populations Living in Karachi''

It is to certify that the above student's thesis has been completed to my satisfaction and to my belief. Its standard is appropriate for submission and evaluation. I have also conducted plagiarism test of this thesis using HEC prescribed software and found similarity index at 7% that is within the permissible limit set by the HEC for the MPhil degree thesis. I have also found the thesis in a format recognized by the BU for the MPhil thesis.

Principal Supervisor's Seal & Signature:


PROF. DR. AMBREEN USMANI
MBBS, Mphil (Anatomy), MCPS (HPE)
PGD (Bioethics) Ph.D (Anatomy)
Vice Principal
Head of Department (Anatomy)
Bahria University Medical & Dental College Karachi.

Date: 23rd September 2019

Name: Prof. Dr. Ambreen Usmani

THESIS COMPLETION CERTIFICATE

Student's Name: Dr. Quratulain Javaid

Registration No: 55007

Program of Study: MPhil Anatomy

Thesis Title: Anatomical Variations of Frontal Sinus Among Ethnic Populations Living in Karachi''

It is to certify that the above student's thesis has been completed to my satisfaction and to my belief. Its standard is appropriate for submission and evaluation. I have also conducted plagiarism test of this thesis using HEC prescribed software and found similarity index at 7 % that is within the permissible limit set by the HEC for the MPhil degree thesis. I have also found the thesis in a format recognized by the BU for the MPhil thesis.

Co-Supervisor's Seal & Signature:


VICE CHANCELLOR
JINNAH SINDH MEDICAL UNIVERSITY
KARACHI

Date: 23rd September 2019

Name: Prof. Dr. Tariq Rafi

PLAGIARISM UNDERTAKING


I, solemnly declare that research work presented in the thesis titled "Anatomical Variations of Frontal Air Sinus Among Ethnic Populations Living in Karachi"

is solely my research work with no significant contribution from any other person. Small contribution / help wherever taken has been duly acknowledged and that complete thesis has been written by me.

I understand the zero tolerance policy of the HEC and Bahria University towards plagiarism. Therefore I as an Author of the above titled thesis declare that no portion of my thesis has been plagiarized and any material used as reference is properly referred / cited.

I undertake that if I am found guilty of any formal plagiarism in the above titled thesis even after award of MPhil degree, the university reserves the right to withdraw / revoke my MPhil degree and that HEC and the University has the right to publish my name on the HEC / University website on which names of students are placed who submitted plagiarized thesis.

Student / Author's Sign: _____



Name of the Student: Dr. Quratulain Javaid

DEDICATION

*I would like to dedicate this thesis to
My beloved parents (Azhar Javaid) and (Sitara Jabeen)
for their selfless and unconditional love*

ACKNOWLEDGEMENTS

First and foremost, I thank Allah (SWT) for listening to my prayers and for bestowing the power to finish my work on time.

Special mention goes to my enthusiastic supervisor, Prof. Dr. Ambreen Usmani, Vice Principal and Head of Anatomy Department, BUMDC for the continuous support of my thesis study and related research. I am very much obliged to her for the boost and motivation provided. She has always stimulated me to do work of finest quality. She is certainly a mentor for me and has always guided me with great patience. For me she is a true inspiration.

Besides my advisor, I would like to thank my teacher and Co-Supervisor, Prof. Dr. Tariq Rafi. Vice Chancellor, JSMU for the encouragement provided throughout the period from the beginning of the thesis until the end. Sir, had you not been there, I would have not thought of such a relevant topic for research.

My profound thanks to my sister, Dr. Nida Azhar, Assistant Professor, NED University for keeping my morale high. She was constantly there for me when I was down. She was the one who enhanced my confidence in those times when I thought I could no longer continue doing this difficult task. I have absolutely no words to thank her. Through thick and thin, she was always there for me. She is certainly a blessing for me.

I would like to thank the librarian, Mr. Ghulam Ashdar for always being helpful. I would have not completed my thesis work with relevant referencing, had he not been there. He had always put extra effort to download original articles that were out of my reach.

My sincere thanks to the senior faculty members of my department. Prof. Dr. Aisha Qamar has been kind and helped me whenever I needed.

I am grateful to Dr. Yasmeen Meher for always acting like a healer. She has always been a great supporter in times when I was down.

I am thankful to Dr. Sama-ul-Haque for providing direction and giving tips to manage time. His guidance has certainly assisted me to discipline in terms of time management.

My profound thanks to my colleague Dr. Hina Faisal from the Pathology Department for encouraging me not to lose hope when I was under immense stress due to my father's health.

I am extremely thankful to Adeel, a technician in ward 2 of Radiology ward, JPMC for helping me collecting data.

Immense gratitude for Mr. Alam, Head of technicians, JPMC, Radiology ward. He helped me in gathering data throughout the project.

My work could not have been finished, had my husband not there for me. He used to spend his leisure time on weekends in visiting JPMC for my research, be it numerous times going for the collection of Institutional Review Letter from the administration block or the gathering of the data; he was always there for me.

I am short of words to show my gratitude towards my parents. My father who had two consecutive surgeries in a short span of time was always praying for my success. He is the one who could foresee that I could become a doctor.

I owe a lot to my loving mother. I would like to express my sincere appreciativeness for her. It is because of her prayers that I am here at the completion period of my thesis work. She has made me a fighter so that hurdles in the life do not bother much.

Last but not the least; I am very thankful to my darling children. The thesis would not have been finished had my children not patiently waited. There were times when I could not give them enough time but they were uncomplaining and tolerant of the fact that their mother was busy. They used to remind me frequently that I should not worry since they were praying for me. Lots of admiration for their unconditional love.

TABLE OF CONTENTS

S#	CONTENTS	PAGES
	Abstract	1
CHAPTER 1 INTRODUCTION		
	Introduction	3
1.1	Upsurge of the world wide diasters	3
1.2	Identification of the non-decomposed bodies	4
1.3	Identification of the decomposed and mutilated bodies	5
1.4	Skull and its use in the forensic science	6
1.5	Structural anatomy of paranasal sinuses	6
1.5.1	Function of the paranasal sinuses	7
1.6	Anatomy of frontal air sinus	10
1.6.1	Anterior relations of the frontal air sinus	12
1.6.2	Posterior relations of the frontal air sinus	12
1.6.3	Arterial supply of the frontal air sinus	14
1.6.4	Venous drainage of frontal air sinus	15
1.6.5	Nerve supply of frontal air sinus	16
1.6.6	Lymphatic drainage of frontal air sinus	17
1.7	Stages in the development of frontal air sinus	18
1.7.1	The developmental phase of frontal air sinus before birth	18
1.7.2	The developmental phase of frontal air sinus after birth	19
1.8	Forensic anthropology	23
1.9	Radiographic imaging for frontal air sinuses morphology and anthropology	23
1.10	Hypothesis	25

1.10.1	Null hypothesis	25
1.10.2	Alternate hypothesis	25
1.11	Objectives of research	25
1.12	Problem statement/ Problem of the study	25
1.13	Significance of the study	26
1.14	Operational definitions	26
CHAPTER 2 LITERATURE REVIEW		
	Literature review	28
2.1	Unique features of the frontal air sinus in every individual	28
2.2	Anthropological significance of the frontal air sinus	29
2.3	Anatomical variability of the frontal air sinus	31
2.4	Measuring technique of frontal air sinus	32
2.5	Parameters used in radiography for measurement of frontal air sinus	32
2.5.1	Height of right frontal air sinus	33
2.5.2	Height of left frontal air sinus	33
2.5.3	Width of right frontal air sinus	33
2.5.4	Width of left frontal air sinus	34
2.5.5	Area of right frontal air sinus	34
2.5.6	Area of left frontal air sinus	34
2.6	Factors affecting the growth and development of frontal air sinus	34
2.7	Sexual dimorphism of frontal air sinus	35
2.8	Comparison of antemortem radiographs with the postmortem radiographs	38

CHAPTER 3 METHODOLOGY		
	Methodology	39
3.1	Research design	39
3.2	Ethical approval	39
3.3	Setting	39
3.4	Inclusion criteria	39
3.5	Exclusion criteria	40
3.6	Duration of study	40
3.7	Sample size estimation	40
3.8	Sampling technique	40
3.9	Human subjects and consent	41
3.10	Materials	41
3.11	Lab parameters	43
3.12	Methodology/Protocol	44
3.13	Algorithm of the study	49
3.14	Statistical analysis	50
CHAPTER 4 RESULTS		
	Results	51
4.1	Gender wise comparison of right and left frontal sinus mean height	51
4.2	Gender wise comparison of right and left frontal sinus mean width	51
4.3	Gender wise comparison of right and left frontal sinus mean area	51
4.4	Ethnicity wise comparison of frontal sinus mean right height among the male groups	52

4.5	Ethnicity wise comparison of frontal sinus mean left height among the male groups	52
4.6	Ethnicity wise comparison of frontal sinus mean right width among the male groups	52
4.7	Ethnicity wise comparison of frontal sinus mean left width among the male groups	53
4.8	Ethnicity wise comparison of frontal sinus mean right area among the male groups	53
4.9	Ethnicity wise comparison of frontal sinus mean left area among the male groups	53
4.10	Ethnicity wise comparison of frontal sinus mean right height among the female groups	54
4.11	Ethnicity wise comparison of frontal sinus mean left height among the female groups	54
4.12	Ethnicity wise comparison of frontal sinus mean right width among the female groups	54
4.13	Ethnicity wise comparison of frontal sinus mean left width among the female groups	55
4.14	Ethnicity wise comparison of frontal sinus mean right area among the female groups	55
4.15	Ethnicity wise comparison of frontal sinus mean left area among the female groups	55
CHAPTER 5 DISCUSSION		
	Discussion	77
CHAPTER 6 CONCLUSION		
	Conclusion	81
6.1	Recommendations	81
6.2	Strength of study	82
6.3	Limitations of study	82

	CHAPTER 7 REFERENCES AND APPENDICES	
7.1	References	83
7.2	Appendices	101
(A)	FRC Approval letter	101
(B)	ERC Approval letter (BUMDC)	102
	ERC Approval letter (JPMC)	103
(C)	Consent form (English version)	104
	Consent form (Urdu version)	105
(D)	Subject evaluation proforma	106
	Questionnaire	107
(E)	Hospital card	108
(F)	Turnitin Plagiarism Check Report	109

LIST OF TABLES

S#	TABLES	PAGES
1	Gender wise comparison of right and left frontal sinus mean height	56
2	Gender wise comparison of right and left frontal sinus mean width	58
3	Gender wise comparison of right and left frontal sinus mean area	59
4	Ethnicity wise comparison of frontal sinus mean right height among the male groups	61
5	Ethnicity wise comparison of frontal sinus mean left height among the male groups	62
6	Ethnicity wise comparison of frontal sinus mean right width among the male groups	64
7	Ethnicity wise comparison of frontal sinus mean left width among the male groups	65
8	Ethnicity wise comparison of frontal sinus mean right area among the male groups	66
9	Ethnicity wise comparison of frontal sinus mean left area among the male groups	67
10	Ethnicity wise comparison of frontal sinus mean right height among the female groups	69
11	Ethnicity wise comparison of frontal sinus mean left height among the female groups	70
12	Ethnicity wise comparison of frontal sinus mean right width among the female groups	72
13	Ethnicity wise comparison of frontal sinus mean left width among the female groups	73
14	Ethnicity wise comparison of frontal sinus mean right area among the female groups	75
15	Ethnicity wise comparison of frontal sinus mean left area among the female groups	76

LIST OF FIGURES

S#	FIGURES	PAGES
1	Anatomy of paranasal sinuses	8
2	Paranasal sinuses inner structure	9
3	Parts of frontal sinus	11
4	Sagittal section of skull showing location of frontal sinus	13
5	Arterial supply of the frontal air sinus	14
6	Venous drainage of the frontal air sinus	15
7	Nerve supply of the frontal air sinus	16
8	Lymphatic drainage of the frontal air sinus	17
9	Development of frontal air sinus before birth	19
10	Development of frontal air sinus after birth	21
11	STEPHNEX machine used during the research at JPMC	42
12	Positioning of the research subject for the Water's view radiograph	46
13	Methodology for taking measurements	48
14	Gender wise comparison of right and left frontal sinus mean height	57
15	Gender wise comparison of right and left frontal sinus mean area	60
16	Ethnicity wise comparison of frontal sinus mean right and left height among the male groups	63
17	Ethnicity wise comparison of frontal sinus mean left area among the male groups	68
18	Ethnicity wise comparison of frontal sinus mean right and left height among the female groups	71
19	Ethnicity wise comparison of frontal sinus mean left width among the female groups	74

LIST OF ABBREVIATIONS

S#	ABBREVIATIONS	STANDS FOR
1	DICOM	Digital Imaging and Communications in Medicine
2	RT HEIGHT	Right height
3	LT HEIGHT	Left height
4	RT WIDTH	Right width
5	LT WIDTH	Left width
6	RT AREA	Right area
7	LT AREA	Left area
8	cm	Centimeter
9	cm ²	Square centimeter

ABSTRACT

Brief background

Human civilization demands identification of the individuals. Both alive as well as the deceased need to be identified. With the rise of mass destruction and catastrophe in this era, the identification of the bodies has become an extremely difficult task for the investigation teams. The Forensic science experts and anthropologists are devising newer methods of identification. In cases where there are mutilated or skeletonized bodies in which soft tissue is lost, the techniques of finger printing and DNA analysis cannot be applied. Radiography of the bony structures is a method of choice in such circumstances as they are strong enough to remain intact after fatal calamities. Frontal sinuses are within strong bones and escape damage even when someone experiences blast injuries, putrefaction or decomposition.

Since variations in anatomy of frontal air sinuses are present among people belonging to different regions of the world, it is important to conduct a study to acquire the parameters of frontal sinus in different ethnicities of Pakistan. This knowledge can help forensic experts to identify the gender as well as ethnicity of the person in cases of disasters like blast injuries where human remains are disfigured or burnt.

Objectives

- To determine the morphology and dimensions of frontal air sinuses in different ethnicities living in Karachi.
- To record variation in dimensions of frontal air sinuses in male and female genders living in Karachi.

Subjects, Materials and Methods

The study design was cross sectional–descriptive. The number of total subjects was 216. They were divided into four ethnic groups with 54 members in each group. Each ethnic group was further divided into male and female sub groups with 27 members in each.

The subjects were sampled by purposive sampling. The subjects were recruited from the radiology department, JPMC, Karachi. The mean age of the subjects was 35.14 ± 8.68 years. Water's view radiography was done in the room number 2 of the radiology ward. The height, width and area of the frontal air sinuses were calculated. The measurements were done by the DICOM digital software.

Results

The height, width and the areas of frontal sinuses on either side were highly significantly greater in the males as compared to the females ($p=0.000$). The highly significant variations existed amongst the four male and female ethnic groups in terms of height, width and area both in the right and the left frontal air sinuses ($p=0.000$).

Conclusion

The height, width and area of frontal sinuses were greater in the males as compared to the females on both the left and the right sides. These dimensions also showed significant variability among the male and female ethnic groups.

Key words

Frontal sinus, anthropology, sexual dimorphism, forensic science

INTRODUCTION

The humans living in a society have their specific identities. The living individuals are named and they are known to others by their personal appearance. Their personal information is saved on the data banks. The enrolled information is important for various reasons that include health, crime, citizenship and educational requirement etc. As the identity of the living is important, similarly it is vital to know the identification of the deceased. The deceased identification is important also in instances where there are catastrophes like typhoons, earthquakes, bomb blasts, tsunamis, medicolegal, social and financial matters (Ciaffi, Gibelli, & Cattaneo, 2011; Gowland & Thompson, 2013; Kumar, Athota, Rastogi, & Karumuri, 2015).

It has been reported that over a period of last ten years the disaster rate and the casualties related to those incidents have amplified (Culver,Rochat, & Cookson,2017). When dead bodies are intact in shape and organization, they are identified on the basis of structural anatomy of faces. In instances when the bodies are severely damaged and disguised, other methods need to pin point identification.

1.1 Upsurge of the worldwide disasters

The rise of catastrophes is recorded and documented both for natural as well as human involved criminal acts (Latham, Bartelink, & Finnegan, 2017). This situation has created an important yet difficult task of personal identification for the forensic team experts (Lynn & Lieberman, 2019; Zin, Ishigami, Shinkawa, & Nishii, 2018).

A cross sectional research has reported, 115 disasters and 3075 casualties between 2000-2009 (Kim, Lee, Park, Kwak, & Han, 2013). A research article published in Lancet documented the increase of human terrorist activities. After the terrorist attack of 2015, France was targeted again in 2016. This resulted in four hundred plus injuries and death

of 86 people (Carles, Levraut, Gonzalez, Valli, & Bornard, 2016). A report on terrorist activities in Pakistan has mentioned increase in the incidence of such activities from 2011 to 2015 (Chaudhary, Lemos, & Van Reenen, 2018).

The identification of affected human bodies is a complicated chore be it associated with the natural disasters like tornadoes, hurricanes, earthquakes, floods, volcanoes eruption, tsunamis or deadly targeted operations like suicide bombings (Latham et al., 2017).

The technology involved in forensic anthropology uses the knowledge of the subject of anatomy to ascertain the characteristics of the human body. Several years of the research and experimentation has led to the evolvement of several procedures that lead to discerning of human bodies. This field involves ongoing and continuous research. Detailed analysis and interpretation are required to pin point the identity of the individuals with great certainty and conviction. The investigation requires keen examination of the body's structural organization and details at the spot of the tragic incident (Ubelaker, Shamlou, & Kunkle, 2018).

1.2 Identification of the non-decomposed dead bodies

There are several ways adopted by the forensic experts to identify those bodies in which the identity cannot be established due to defacement and disfigurement.

Soft tissue prints imaging is one of the methods that involves examination of fingerprints and lip prints (Dhall & Kapoor, 2016; Ahmed, Salem, & Fawzy, 2018). This methodology has proved to be dependable in the identification process. The main technique employed in finger printing is by the use of dermatoglyphics. It involves the observation of anatomical patterns of ridges present in the epidermal layer of the skin. This methodology can be useful in solving the mysteries involved in the medico-legal cases (Oktem et al., 2015).

Cheiloscopy or lip printing has also been proposed as one of the ways to identify individuality. A cheiloscopy study was done on two hundred study subjects, hundred from Maharashtra and hundred from Kerala. None of the participants were found to have same lip prints (Ashwinirani et al., 2014).

Research has documented the role of DNA examination and technique of PCR in the identifications of human remains (Moretti et al., 2016). The DNA analysis is a biochemical method of identification. It has proven useful for the forensic scientists and the anthropologists (Calafell & Larmuseau, 2017; Crawford & Beaty, 2013). The interpretation using the DNA methodology can be employed with ease when the available DNA sample's condition is appropriate to be used in the laboratories (Edson et al., 2018). Victims of disasters can be identified with reliability using the DNA analysis and profiling procedure. The technique requires the DNA sample to be in such a state so that the quality of the sample does not compromise the result. It is also necessary to have ante mortem sample for its comparison with the post mortem sample (de Boer et al., 2018). A recent research has documented the unpredictability in identification of individuals while using DNA samples from the site of suicide blast (Rampant, Coumbaros, & Chapman, 2019).

The techniques of the soft tissue printing as well as DNA examination and sampling have shown remarkable results in the fields of forensic science and anthropology. These methods can only show great attainments provided the bodies are not burnt and decomposed.

1.3 Identification of the decomposed and mutilated dead bodies

In cases where soft tissue is lost due to extremes of temperatures or decomposition, anthropological studies depend on the bones of the body. The bones are stronger enough to remain intact after fatal disasters. Among the anthropological identification tools, skulls are helpful in identification (Patil & Mody, 2005). The parts of the skull have characteristic features. They are a valuable source in cases where the body's soft tissues

are lost and it is in decomposed state (Kanjani, Rani, & Kanjani, 2019; Silva, Mundim, Picoli, & Franco, 2015; Viner, 2018).

The parts of the skull used for human identification include the nasal septum, mastoid process, sella turcica, teeth and para nasal sinuses (Cox, Malcolm, & Fairgrieve, 2009).

The simple yet cost effective technique of radiology can serve as an effective tool in the process of identification of victims. It has become an integral component of the forensic science (Raina, Ravindra, Malik, & Yeluri, 2019; Tarani, Kamakshi, Naik, & Sodhi, 2017; Vallis, 2017; Viner & Robson, 2017).

The superimposition techniques involving the structures of the human skulls have helped in identification of deceased (Milligan, Finlayson, Cheverko, & Zarenko, 2018).

1.4 Skull and its use in the forensic science

The anatomy of the paranasal sinuses can help the forensic anthropologists in human identification due to the peculiar characteristics which are unique to all human beings (Alrumaih, Ashoor, Obidan, Al-Khater & Al-Jubran 2016; Alshaikh & Aldhuraish, 2018; Amusa et al., 2011; Fernandes, 2018; Kumar, Rakesh, & Prasad, 2016).

The frontal sinuses anatomy has proven to be useful due to their distinctive features (Cossellu et al., 2015; Ubelaker et al., 2019). Over the years with the advancements of the techniques and increased research work, usefulness of frontal sinuses anatomy in personal identification cannot be overlooked. An article documented the matching and comparison of the frontal sinuses. Similarity of anatomical structures were documented in terms of the antemortem and the postmortem findings (Ferreira, Fortes, de Lucena, Gomes, & Franco, 2017).

1.5 Structural anatomy of the paranasal sinuses

Paranasal air sinuses are air-filled spaces that are present within the bones of skull. There are four pairs of paranasal air sinuses, frontal, ethmoid, maxillary and sphenoid. In humans, the development of the paranasal sinuses exhibit several variations. The

embryonic developmental phase of paranasal sinus growth starts in the third week of gestation. The growth and increase in the size of the paranasal sinuses continues after the birth and continues in the initial stages of adulthood period (Korkmaz, 2013).

The research has documented that the paranasal sinuses development is not even same in the monozygotic twins (Kjær, Pallisgaard & Brock-Jacobsen, 2012).

The location of the paranasal sinuses is around the nasal region within the skull. Three common anatomical structures that are present in all four paranasal sinuses are the lining mucosa, the presence of cilia and ostea. The ostea of the paranasal sinuses are located within the sinuses for the drainage purpose (Stamm, 2000).

The frontal sinuses are located above the region of the eyes within the frontal bone. The ethmoidal sinuses are located within the ethmoid bone. The maxillary sinuses are located within the maxillary bone and the sphenoid sinuses are located within the sphenoid bone. All the four sinuses in the skull are drained through small openings in the lateral wall of the cavity of nose (Cappello & Dublin, 2018).

The epithelium lining the mucosa is pseudostratified columnar. At the time of birth, most of the sinuses are either not present or if present, are rudimentary in size. The size and growth increases during the eruption period of teeth (Henson & Edens, 2018).

1.5.1 Function of the paranasal sinuses

There are several functions; the main functions include

- Decrease the weight of the skull
- Are helpful in voice resonance function
- Act as air humidifiers
- Aid in heating of the air that is inhaled
- Prevent the temperature fluctuation in nose
- Protect structures within the skull during trauma (Henson & Edens, 2018)

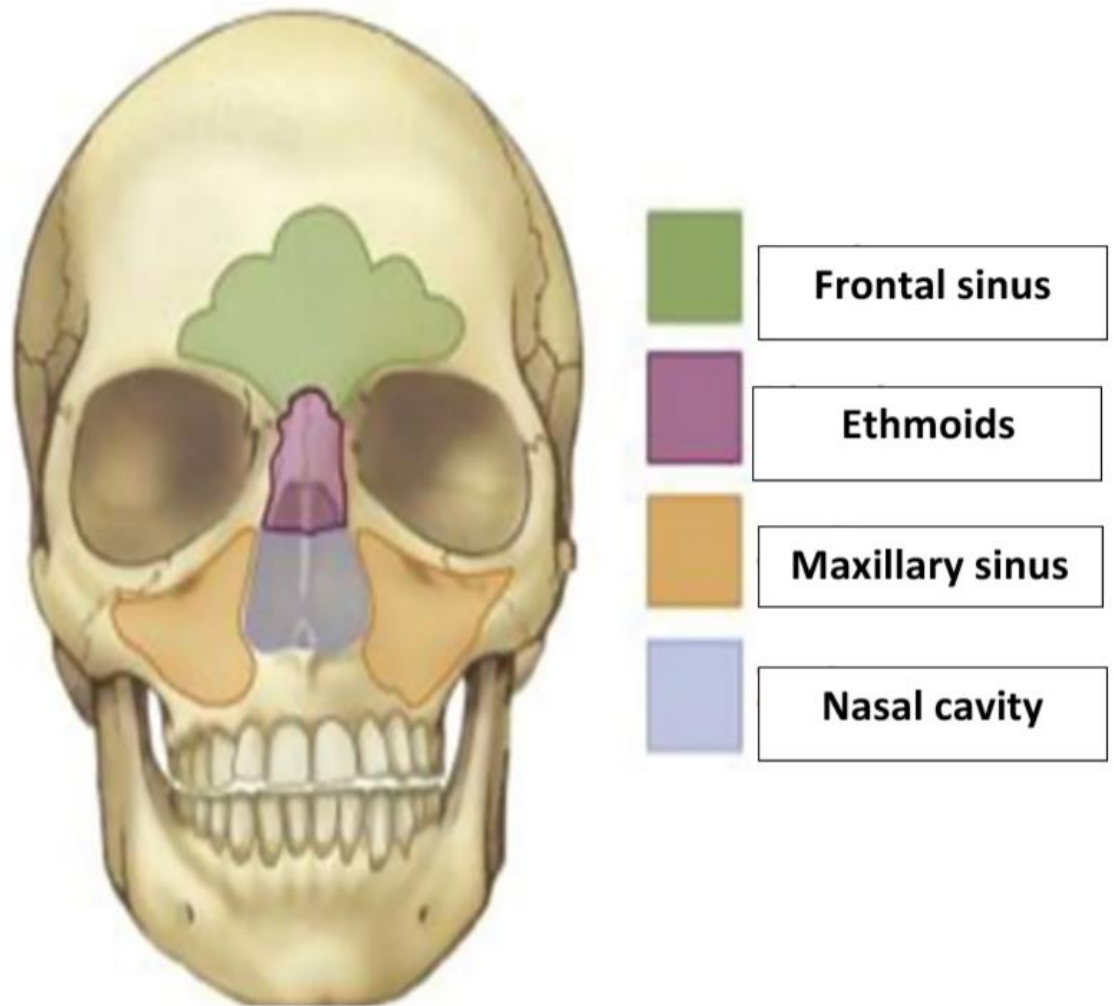


Figure 1: Anatomy of Paranasal sinuses

Drake, R., Vogl, A. W., & Mitchell, A. W., 2019: Gray's Anatomy for Students.

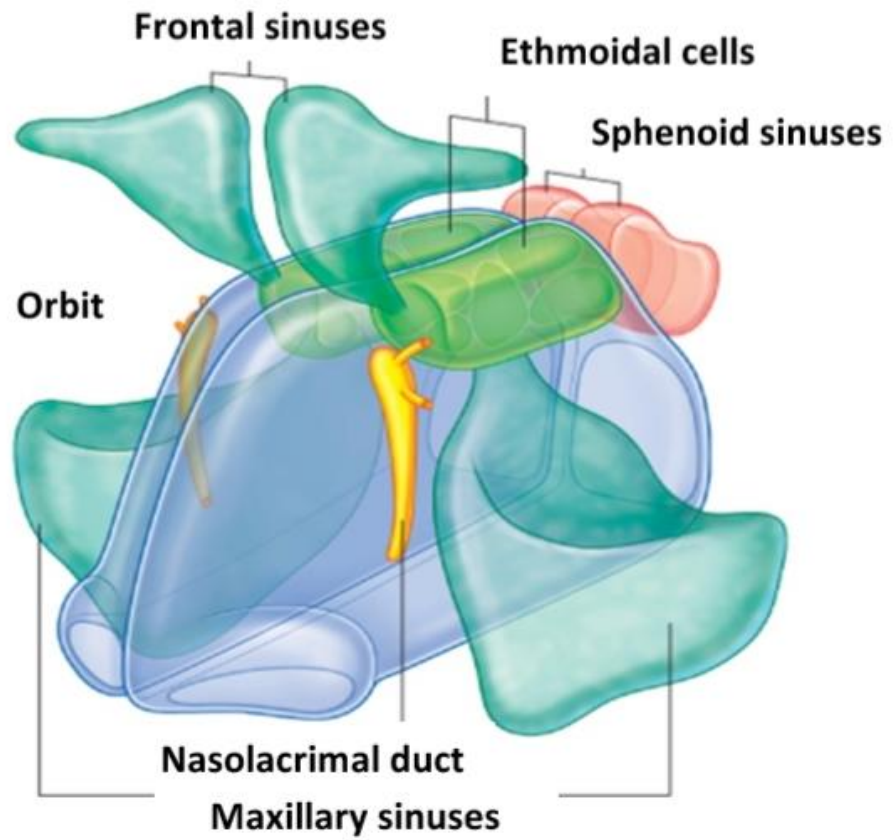


Figure 2: Paranasal sinuses inner structure

Drake, R., Vogl, A. W., & Mitchell, A. W., 2019: Gray's Anatomy for Students.

1.6 Anatomy of frontal sinuses

Frontal air sinuses are two in number and are present in between the outer and inner tables of the frontal bone. The anterior part of the boundary of the sinus is thicker as compared to the posterior boundary. The thickness of the anterior wall ranges from 4 to 12 mm. Frontal air sinuses anterior wall begins at the level of the frontonasal suture and it extends till the area of frontal protuberance. The posterior wall of the frontal air sinus being a thinner layer, measures less than a millimeter. The posterior walls contribute in the formation internal frontal crest that receives the insertion of the falx cerebri (Duque & Casiano, 2005).

The frontal sinuses are present behind the superciliary arches on the superior aspects of the orbits. The sinuses on either side are located along a triangular area. The boundaries of the triangular area are angled at the region of nasion, three cm above the region of nasion and at a point that is located at the junction of lateral two third and medial one third of supraorbital area (Standring, 2015).

The two sinuses are separated from each other by the presence of a central septum. The median septum is present in the region of the posterior aspect of the superciliary ridge. The frontal air sinuses present on the two sides are not morphologically same (Aslier et al., 2016).

The midline septum in between the two frontal air sinuses is not in line with the mid sagittal plane (Nikolova, Toneva, Georgiev & Lazarov, 2018). The asymmetrical pattern of the dimensions of the frontal air sinuses is also attributed to the deviation of the central septum from the midline (Sinnatamby, 2011).

Each frontal sinus has two parts; frontal part and the orbital part. The frontal part of the frontal sinus is located on the superiomedial part of the eyebrow. The orbital part of the frontal sinus has extensions reaching the area occupied by the medial part of the roof of the orbits. The posterior region of the frontal sinus has extensions near lesser wing of sphenoid. The frontal air sinuses are lined by mucoperiosteum. The frontal air sinuses are

drained in the region of middle meatus through the frontonasal ducts. The frontonasal duct penetrates the ethmoidal labyrinth's anterior region (Standring, 2015). The frontal recess is present in between the frontal sinuses and the semilunar hiatus (Cappello & Dublin, 2018).

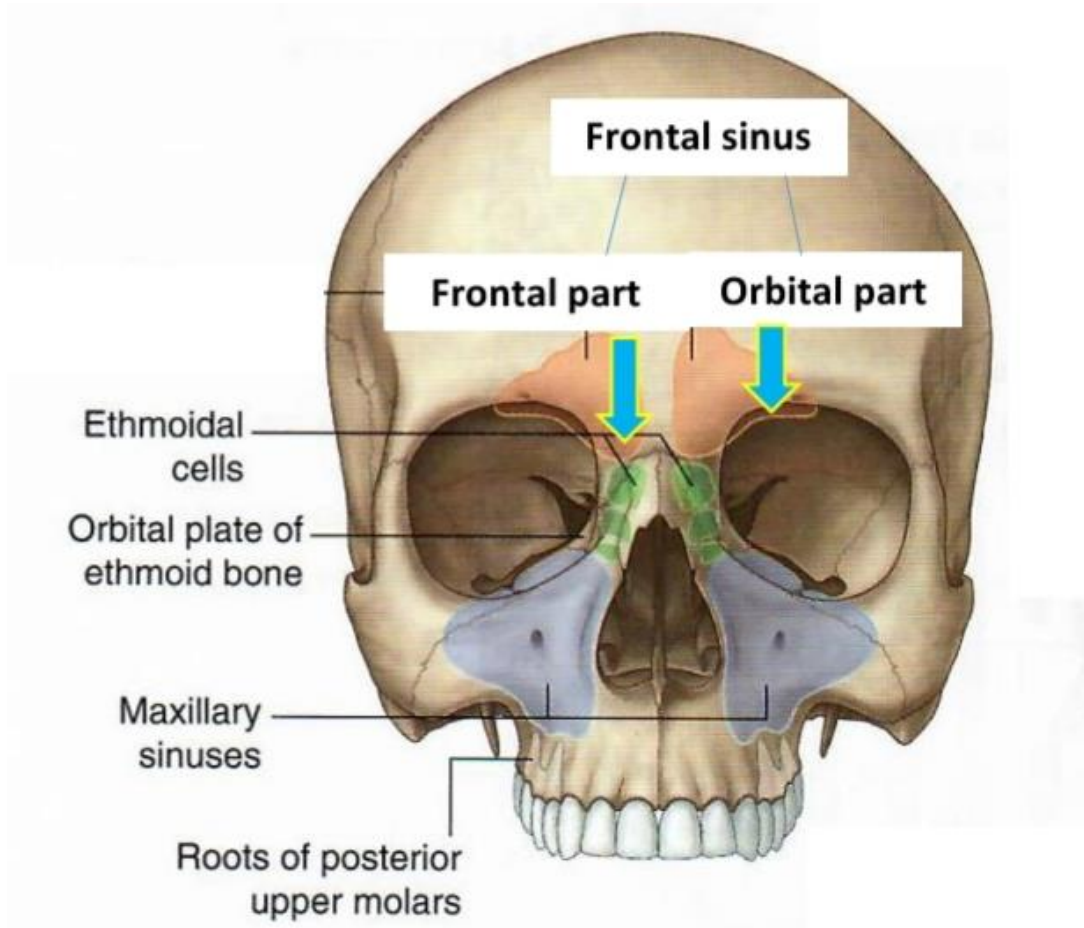


Figure 3: Parts of frontal sinus

Drake, R., Vogl, A. W., & Mitchell, A. W., 2019: Gray's Anatomy for Students.

There are four types of frontal cells. Type I is a single cell that lies below the frontal sinus region and above the agger nasi. The type II frontal cells are tier of cells present above the agger nasi. Type III frontal cell is a single cell that passes through the outer table of the frontal sinus. The type IV cells are present within the frontal sinus (Hiatt & Gartner, 2009).

The roof of the nose is in close proximity to the sinuses. The average height of frontal sinus is 3.2 cm, average width is 2.6 cm, while the depth is 1.8 cm. The frontal sinus is not present at the time of birth or very small in size if present. It is grown well by the age of seven to eight years. The maximum dimensions of the frontal air sinuses are formed after the period of puberty (Standring, 2015). The growth of the frontal air sinuses is completed by the age of twenty years (Christensen, & Hatch, 2018).

1.6.1 Anterior relations of the frontal sinuses

The structures which are present anteriorly to the frontal sinus from superficial to deep are skin, superficial fascia, the frontalis muscle and the periosteum lining the frontal bone.

1.6.2 Posterior relations of the frontal sinuses

The posterior wall of the frontal air sinuses forms the inferior and the anterior margin of the anterior cranial fossa. There are two structures in close proximity; the dura mater and the frontal lobe of the cerebral cortex (Duque & Casiano, 2005).

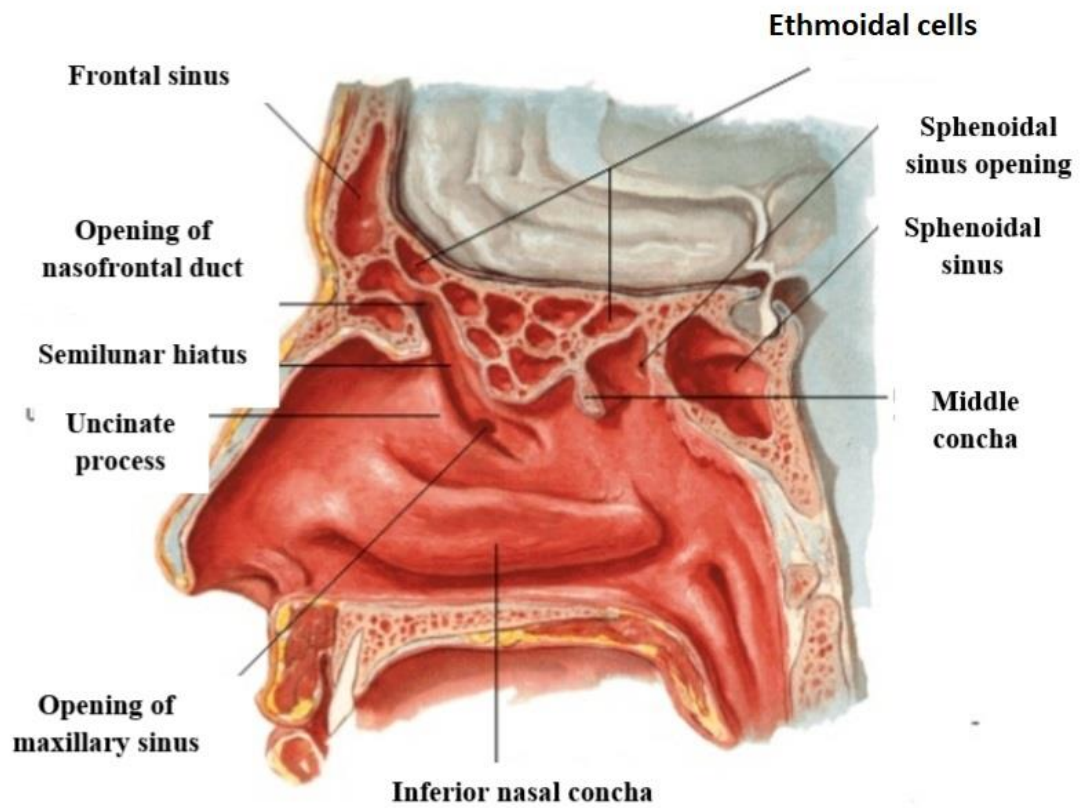


Figure 4: Sagittal section of skull showing location of frontal sinus
 Netter, F. H., 2017: Atlas of Human Anatomy.

1.6.3 Arterial supply of the frontal air sinuses

The two sinuses are supplied by the supra orbital and the anterior ethmoidal arteries. Both the arteries are the branches of the ophthalmic artery (Standring, 2015).

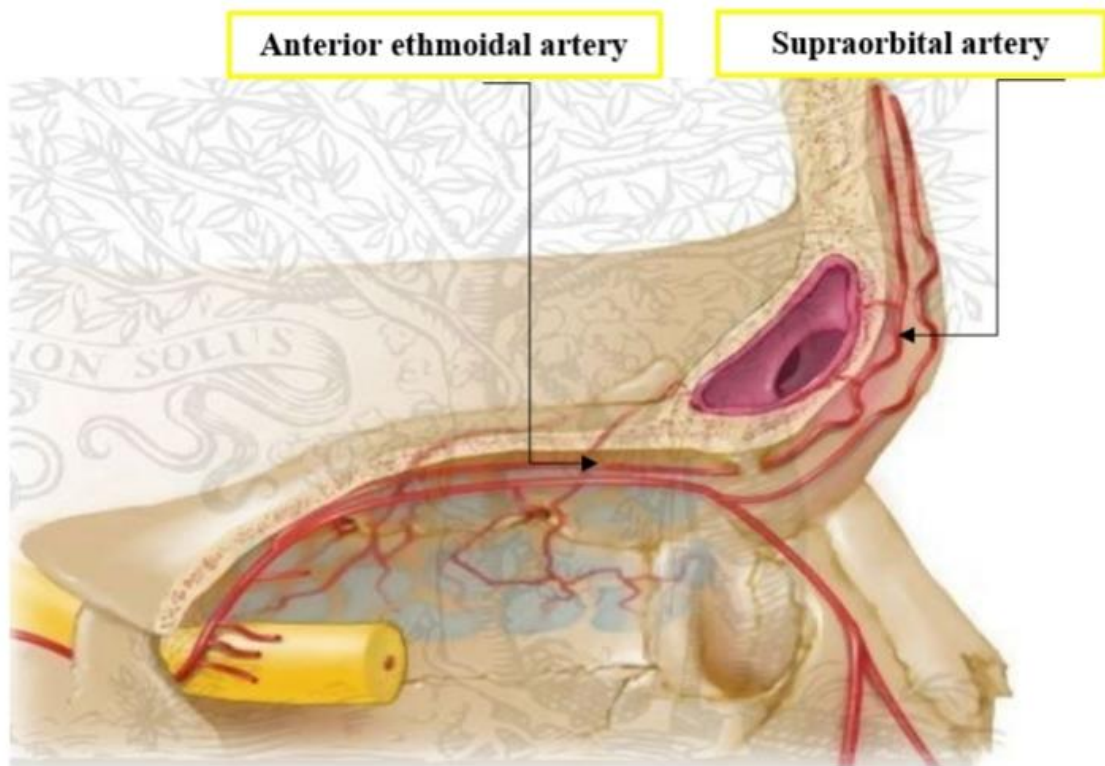


Figure 5: Arterial supply of the frontal air sinus
Netter, F. H., 2017: Atlas of Human Anatomy.

1.6.4 Venous drainage of the frontal air sinuses

There are two veins, which are associated with the venous drainage of the frontal sinuses. It is through the supraorbital and the ophthalmic veins. The veins pass in the region of the supraorbital notch (Standring, 2015).

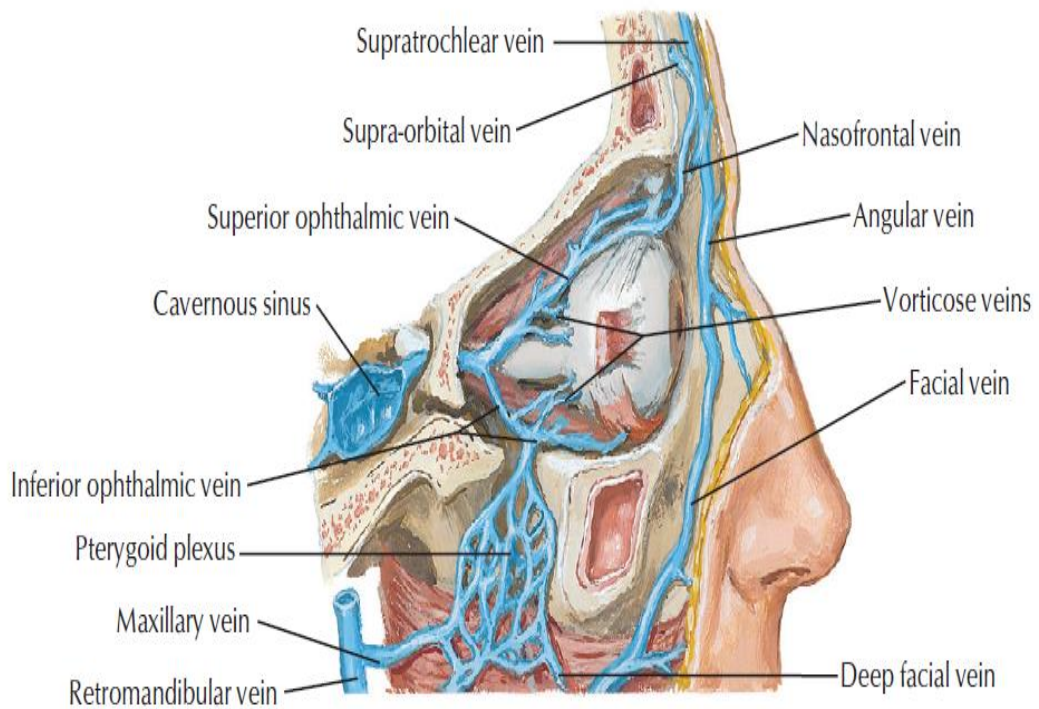


Figure 6: Venous drainage of the frontal air sinus
Netter, F. H., 2017: Atlas of Human Anatomy

1.6.5 Nerve supply of the frontal air sinuses

The nerves supply is through the supraorbital and supratrochlear nerves. Both the nerves belong to the ophthalmic nerve. The ophthalmic nerve is the first division of the fifth cranial nerve (trigeminal nerve) (Cappello & Dublin, 2018).

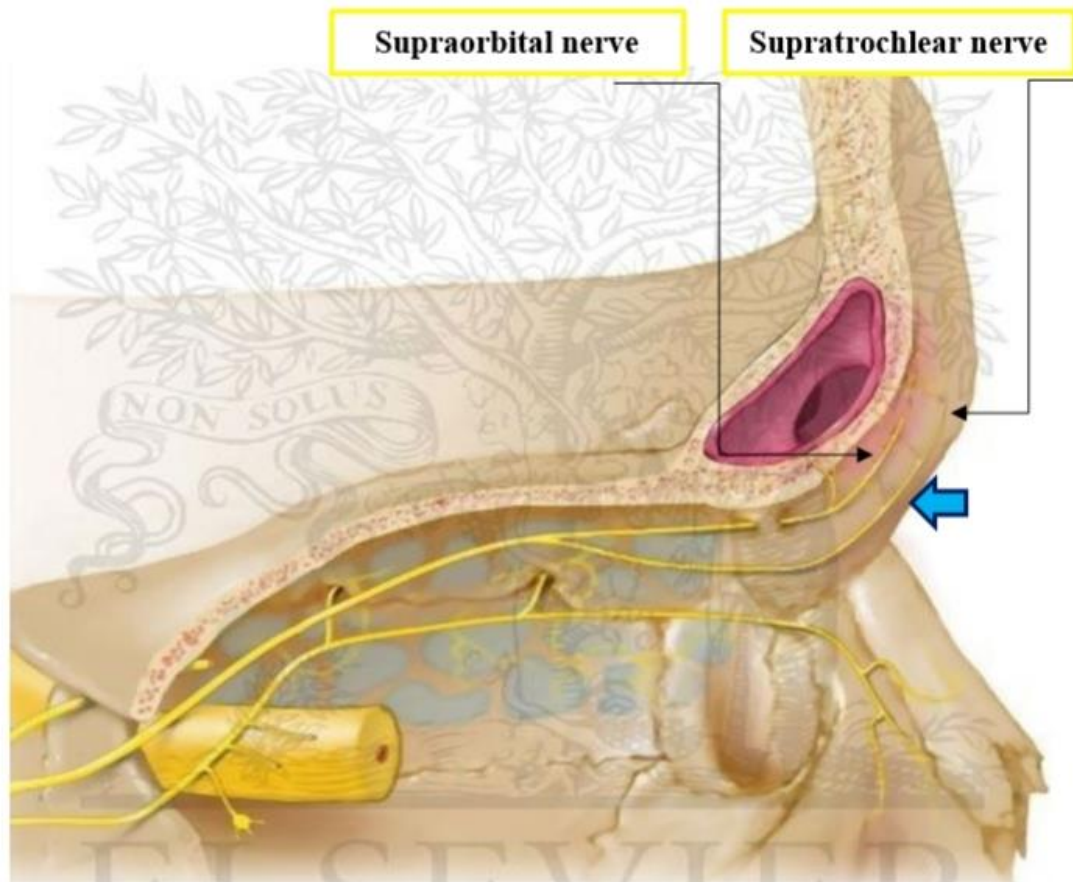


Figure 7: Nerve supply of the frontal air sinus
Netter, F. H., 2017: Atlas of Human Anatomy.

1.6.6 Lymphatic drainage of the frontal air sinuses

The lymphatic vessels arise from the mucosa lining the frontal air sinuses. The lymph is taken by the lymphatics. The lymph from the region of the frontal sinuses drains in the submandibular lymph nodes, which lie deeply within the substance of the submandibular salivary glands. (Zha, Gao, Zhu, & Gao, 2018).

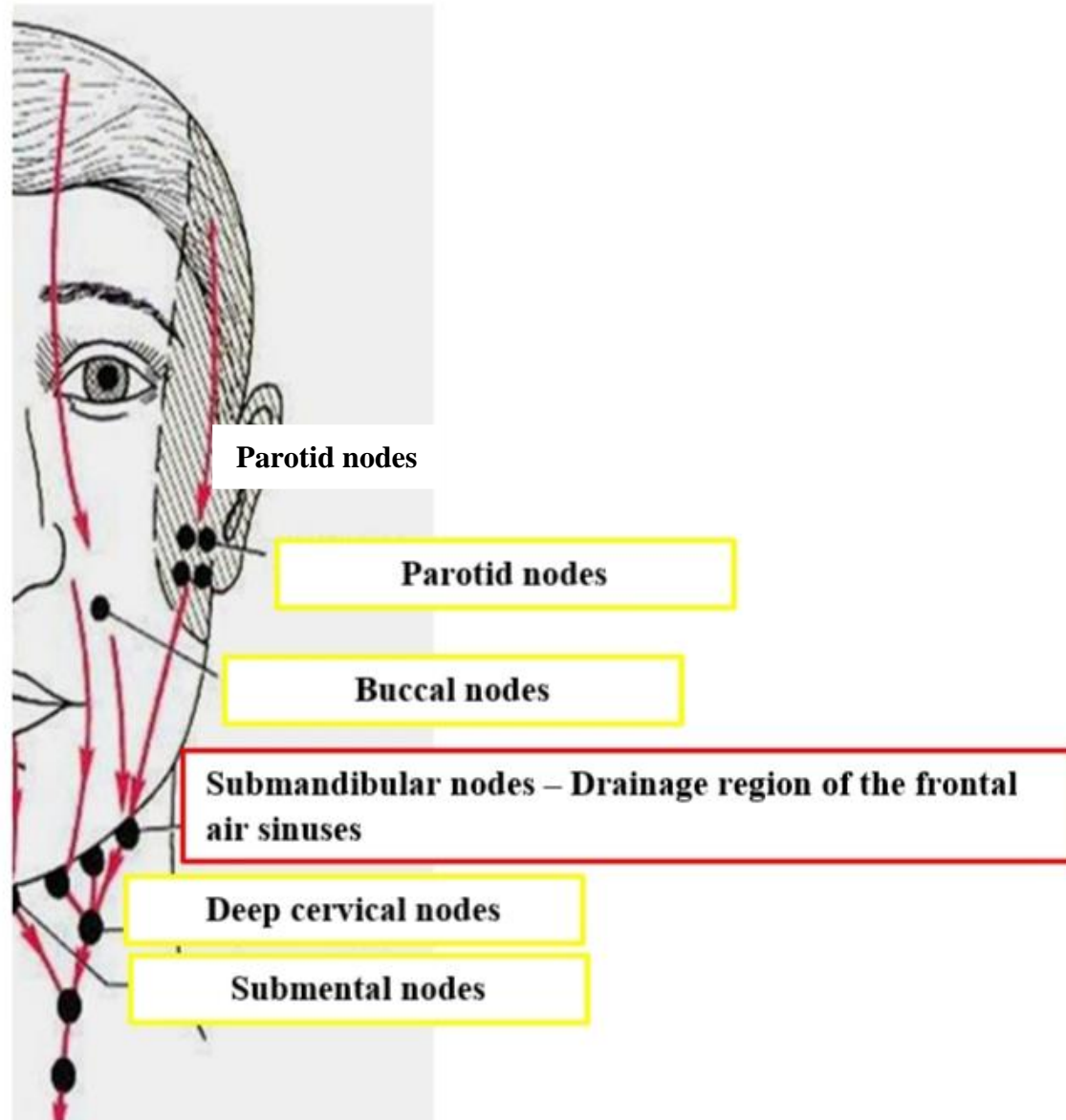


Figure 8: Lymphatic drainage of the frontal air sinus
Netter, F. H., 2017: Atlas of Human Anatomy.

1.7 Stages in the development of frontal air sinuses

Out of the four paranasal sinuses, the frontal sinus is the last to develop. Its development begins before birth and continues after the birth till eighteen years of age (Duque & Casiano, 2005). At birth, frontal sinus presents in the form of a tiny depression or a furrow (Vaid & Vaid, 2015).

1.7.1 The developmental phase of frontal air sinuses before birth

The embryological development of the frontal air sinuses begins in the sixteenth week of the development. It develops slowly either as diverticula from lateral nasal wall or the anterior ethmoidal cells travel towards the region that lies in between the outer and the inner region of the frontal bone (Duque & Casiano, 2005; Villareal et al., 2019).

The diverticula or recess may also arise from the region of the infundibulum (Demiralp et al., 2018). The embryonic development of the frontal air sinuses was documented to occur from the anterior ethmoidal sinuses as well (Villareal et al., 2019).

The sinuses are very small initially and may be as the size of the pea. They begin to develop on the sides of the glabella above the orbits on each side (Nikolova et al., 2018).

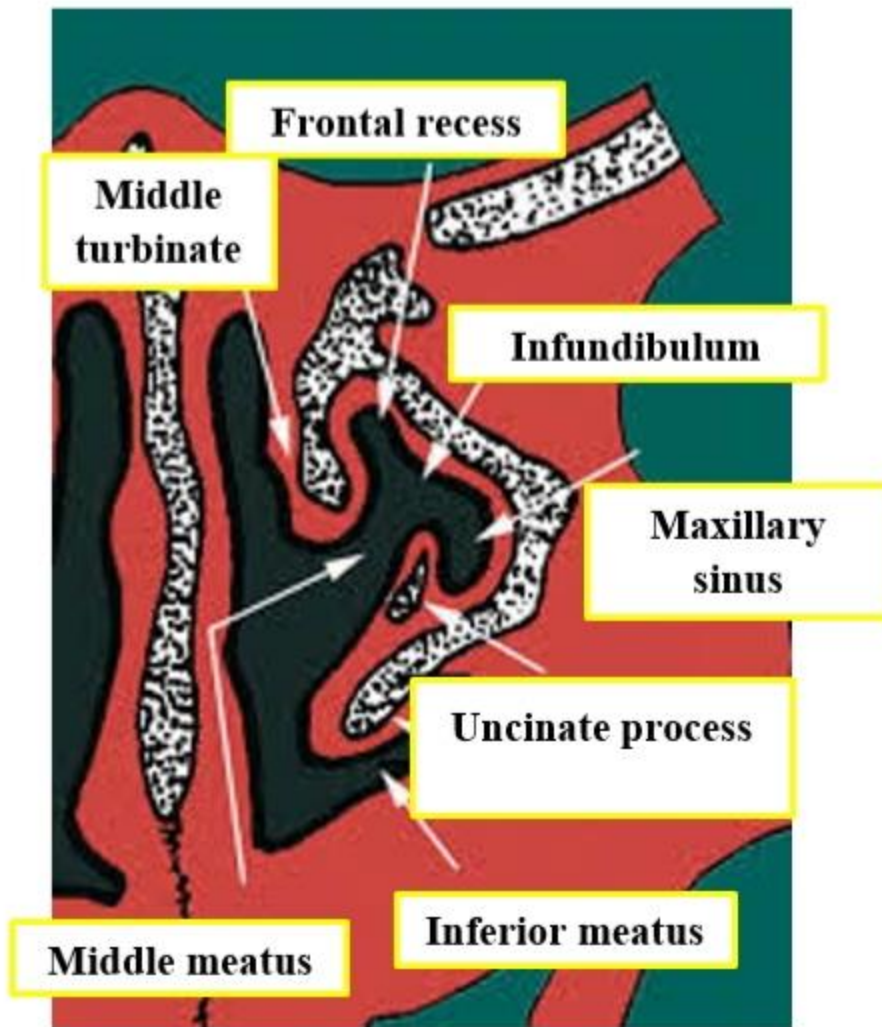


Figure 9: Development of frontal air sinus before birth
 Duque C. S. & Casiano, R. R., 2005: The frontal sinus.

1.7.2 The developmental phase of frontal air sinuses after birth

The frontal bone of the skull is a type of a diploic bone. There is presence of spongy bone between the inner and the outer zones of the frontal bone. The growth of frontal air sinuses is dependent on the resorption of the diploic bone in between the inner and the outer tables of the frontal bones (Nikolova et al., 2018).

The elongation and the change of shape of the inner table of frontal bone is related to the growth of the frontal lobe of the brain. As soon as the growth of the frontal lobe of the brain ceases, the inner table also stops changing its shape. This occurs by the period, which ranges from six to seven years of age. The outer table of the frontal bone continues to develop even after the period when the inner table ceases to alter its shape. The shape of outer table depends on the growth of frontonasal and maxillary bones growth (Shapiro & Schorr, 1980).

There are three phases in the development of the frontal sinuses. The first phase of the development starts after the age of six years. The second phase starts before the period of puberty. The second phase in comparison to the other phases is slow in growth. The last and the third stage starts during the period of puberty. Third phase of development is associated with many changes in the structure as compared to the other two phases. The phases of development are of high significance in discerning age of individuals who have not entered adulthood (Moore & Ross, 2017).

There are two stages of pneumatization involving the frontal air sinuses. These phases are known as primary and secondary stages of development. In the primary stage of pneumatization the frontal sinuses develops at a slow pace until the age of one year. The secondary stage of pneumatization follows the primary stage and continues until the eighteen years of age. Irregular air filled cavities of the frontal sinuses are formed due to the process of pneumatization in the frontal bone. The process of pneumatization differ in every individual (Dafalla, Seyed, Elfadil, Elmustafa, & Hussain, 2017). It has been documented in literature that frontal air sinuses can be identified radiographically only in 1.5 percent of infants who are in age less than one year. By this stage of life, the frontal air sinuses do not expand much and are located at a localized place. The localized places are known as cellulae ethmoidalis. This shows their origin from the ethmoidal cells (Duque & Casiano, 2005).

In literature, variable periods have been reported for completion of growth to full extent ranging from 11 years, 14 years to 20 years (Marsya, Sasmita, & Oscandar, 2017; Moore & Ross, 2017; Nathani et al., 2016).

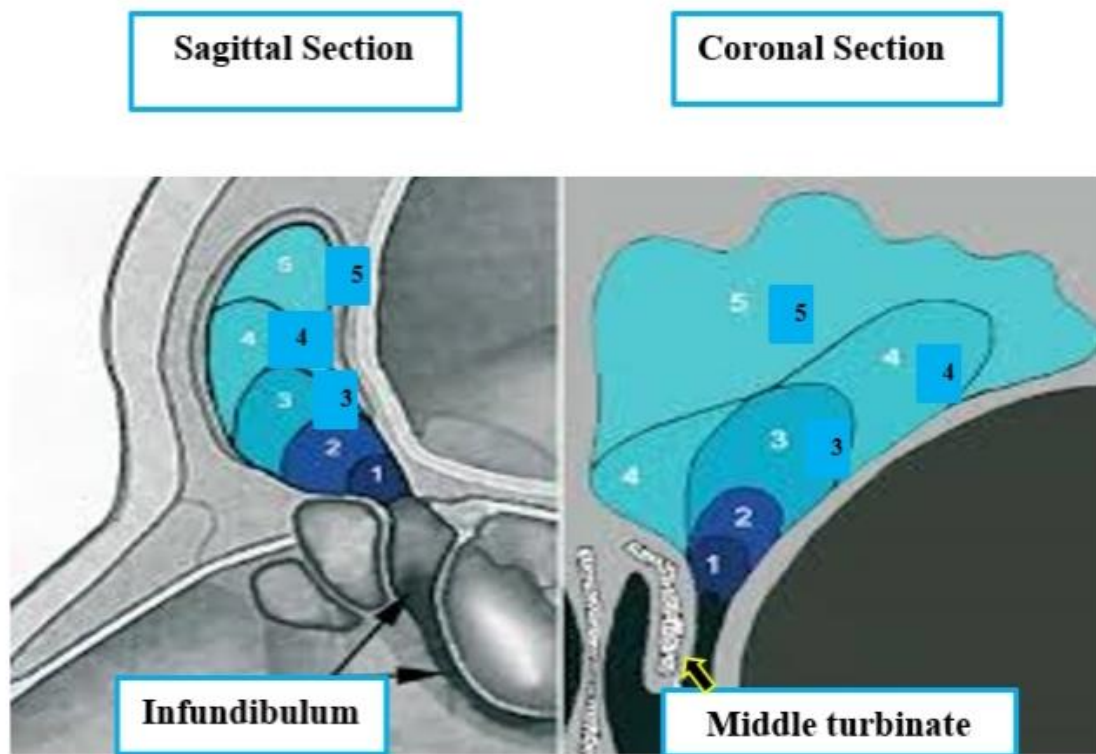


Figure 10: Development of frontal air sinus after birth
Duque C. S. & Casiano, R. R., 2005: The frontal sinus.

Szilvassy (1981) has reported the growth pattern of frontal air sinuses in males and females at different age groups. According to him, there is no difference up to 5 years of age. During 8-12 years, growth is slower in boys. At 14-15 years growth in boys shows acceleration over girls.

A study revealed that frontal sinus growth was related to the growth of the height of the body. At the puberty, the body's height was noticed to be increased along with increase in size of frontal sinus. The frontal growth and increase in size continued even after 1.4 years of peak period of increase of body increase in the height (Ruf & Pancherz, 1996).

The growth of the frontal air sinuses is related to the presence and absence of the metopic suture. Before the birth, there are two frontal bones which are separated from each other by the presence of the metopic suture (Shapiro & Schorr, 1980). The metopic suture closure age varies from first to ten years (Da Silva et al., 2013).

As the metopic suture closes, the frontal sinuses begin their expansion both in the vertical and the orbital planes of the frontal bone. The vertical extension can reach up to the level of squamous part of the frontal bone. The horizontal extension can reach the area above the orbital region. The horizontal extension occurs first and later the vertical extension. The horizontal extension occurs during the first year of post-natal life. The vertical expansion of the frontal air sinuses begins when the child is two years old. The expanded sinuses reach to the level of nasion region by four years. The growth continues till the puberty (Bilgin et al., 2013). The horizontal growth in rare cases can reach to the sites where lesser and greater wings of sphenoid are present. They can even reach to the nasal, temporal and the parietal bones (Shapiro & Schorr, 1980).

1.8 Forensic anthropology

The field of anthropology has discovered and highlighted the importance of gaining insight about the structural anatomy. It uses the knowledge of anatomy in the identification of human bodies of unknown identities (Burns, 2015). The use of radiology was earlier only used by the health experts for the diagnostic purposes (Erturk, Ondategui-Parra, Otero, & Ros, 2006).

Over the years, several researches have been conducted based on forensic anthropology. A total of 1663 research articles which belonged to 219 countries have been published based on anthropology and its importance in the forensic science (Lei et al., 2019).

It is now possible to identify the bodies even in those circumstances when the bodies are severely charred and mutilated (Kumar et al., 2015; Wiersema, 2016).

1.9 Radiographic imaging for frontal air sinus morphology and anthropology

The first study that proposed the use of frontal air sinuses radiographic dimension for identification purpose dates back to 1921. This is considered as a milestone in the field of forensic science. The research was published in Medical Journal of Australia in the year 1943 (Schuller, 1943).

In 1925, another keystone in the radiographic success in identification was achieved. A person was identified by comparison of the two roentgenograms belonging to him. (Culbert & Law, 1927).

In literature, it is documented that frontal sinuses have very strong walls. The tough walls of the sinuses make them stay in their original shape and size even when someone experiences blast injuries, putrefaction or decomposition (Goyal, Acharya, Sattur, & Naikmasur, 2013; Kahali & Tootoonchian, 2015).

Craniofacial variations in size do exist among the human beings. Because both the sinuses develop independently, every individual has frontal sinus variation in size and shape. The findings from the roentgenograms can be applied to the field of forensic sciences and in the investigation of medicolegal cases (Beaini, Duailibi-Neto,

Chilvarquer, & Melani, 2015; Manigandan, Sumathy, Elumalai, Sathasivasubramanian, & Kannan, 2015).

Literature search shows that till now no research paper has been published in Pakistan related to the anatomical variation and its significance in the field of anthropology. Since variations are present among the people living across the world, it is important to conduct a study among different races of Pakistan too.

According to Najam and Mehmood (2019), 289 terrorist activities and 45 natural calamities have been reported in Pakistan. Disasters due to these incidents and otherwise required identification of unknown dead bodies.

This statistics require us to know about the dimensions and location of frontal sinus. The knowledge gained by the research can help forensic experts identify the unknown dead bodies in cases of disasters like blast injuries where human remains are disfigured or burnt.

1.10 Hypothesis

1.10.1 Null hypothesis:

There is no anatomical variance among the frontal sinuses of ethnic populations as well as the males and females living in Karachi

1.10.2 Alternate hypothesis:

There is anatomical variance among the frontal sinuses of ethnic populations as well as the males and females living in Karachi

1.11 Objective/s of Research/ Study

- To determine the morphology and dimensions of frontal air sinuses in different ethnicities living in Karachi.
- To record variation in dimensions of frontal air sinuses in male and female genders living in Karachi.

1.12 Problem Statement/ Problem of the Study

In the present era, deaths due to the fatal explosions and detonations be it natural or human oriented are very common and on a rise. Identification of the dead bodies has become a challenging job for the investigation teams. The forensic anthropologists are working on the new techniques and employing methodologies to cater this problem. The radiographic findings can help in identification of the victims. The technique can be incorporated particularly in those instances where soft tissues are lost and routine procedures like finger printing and DNA samples are not possible. World over, the radiography of frontal sinus is used as a tool in knowing the identity of the dead bodies. In our country, no research has been done employing the use of anatomical features of frontal air sinuses in identification of the deceased.

1.13 Significance of the Study

The present study has been planned to facilitate the forensic team experts and the anthropologists in identification of the unknown deceased by using the knowledge and application of anatomy of frontal air sinuses. The framework of the frontal air sinuses is unique to every person and henceforth, the specific structural details can be used as a tool in the forensic identification. The methodology of the radiography is simple yet cost effective. The procedure of the cephalometry using radiography can be employed with great certainty in the tragedies of mass destruction when there are human remains of unknown and anonymous identity. The study is one of its kind in the country as there was never a research conducted on the anatomical variation of frontal air sinuses in Pakistan. This research aimed to determine that there exists variation in the anatomical details and sexual dimorphism of the frontal sinuses in people belonging to different ethnic groups living in Karachi. The present study can be a baseline in establishing the databases in the health sector and to record frontal sinus radiographic details so that it can be used to match with the postmortem radiographs.

1.14 Operational definitions

Frontal sinus

Frontal sinuses are air-filled spaces that are present within the frontal bones of skull. The frontal sinuses also called sinus frontales and are two in number. They are present in between the outer and inner tables of skull behind the superciliary arches. The two sinuses are separated by a midline septum.

Standring, S. (Ed.). (2015). *Gray's Anatomy International Edition: The Anatomical Basis of Clinical Practice*. Elsevier Health Sciences.

Anthropology

The science of human beings; particularly the study of human beings and their lineages through time and space and in relation to physical appearance, environmental and communal relations, and culture.

Burns, K. R. (2015). *Forensic anthropology training manual*. Routledge.

Sexual dimorphism

It is the condition where the two genders of the same species exhibit different features and structural anatomy other than the variances in their sexual organs.

Rigby, N., & Kulathinal, R. J. (2015). Genetic architecture of sexual dimorphism in humans. *Journal of cellular physiology*, 230(10), 2304-2310.

Forensic sciences

Forensic science is the use of science to criminal and civil laws, mainly criminal investigations, as governed by the legal standards of admissible evidence and criminal procedure.

Katz, E., & Halánek, J. (Eds.). (2016). *Forensic science: A multidisciplinary approach*. John Wiley & Sons.

LITERATURE REVIEW

The proof of the human identity requires a systematic procedure to be followed. In order to establish identity of persons the anatomists and the forensic experts have used several methods (Byers, 2016; Crosta, 2016; Cattaneo, 2017; Goodwin & Simmons, 2017; Konigsberg& Jantz, 2017).

The use of skull in personal identification cannot be denied and the methodology is being used by the anthropologists (González-Colmenares, Medina, Rojas-Sánchez, León, & Malpud, 2019; Manigandan et al., 2015; Rabelo et al., 2016).

2.1 Unique features of the frontal air sinuses in every individual

Certain anatomical features are characteristic and unique for every person. Those structures can be observed by the technique of comparing the antemortem and postmortem radiographs. This involves the use of the superimposition technique. This strategy can be very helpful in the personal identification (Iino, Fujimoto, Yoshida, Matsumoto, & Fujita, 2016; Patil, Karjodkar, Sontakke, Sansare, & Salvi, 2012).

The variation in the anatomical configuration of the frontal air sinuses was observed in a research on the Mexican adults (Cossellu et al., 2015; Galán, Carlos, & Reyes Téllez Girón, 2016). The research has shown and proved the exclusive structure of frontal sinuses (Richer, 2015). The frontal air sinuses are used in the forensic anthropology (Gopal & Vijayan, 2016; Nagaraj et al., 2017).

The unique shape and size of frontal sinus in every individual is due to the independent pneumatization of frontal bone during the developmental period (Nagaraj et al., 2017). As the two sinuses develop individually, there are chances in which one frontal air sinus grows bigger than the other (Gotlib, Kuźmińska, Held-Ziółkowska, Osuch-Wójcikiewicz, & Niemczyk, 2015). The unknown deceased can easily be identified due to the asymmetrical structure of these sinuses that make them incomparable (Gadekar, Kotrashetti, Hosmani, & Nayak, 2019).

Research has documented that the dimensions of the frontal sinuses are distinctive in every individual. When antemortem radiographs are compared with the post mortem radiographs, the individuality and characteristic appearance of the frontal sinus help in identifying the unknown persons. There are differences in the anatomical features of the frontal sinus, both in terms of morphology as well as measurements (Pandeshwar, Kumar, Shastry, Ananthaswamy, & Markande, 2017).

2.2 Anthropological significance of the frontal sinuses

The frontal air sinuses have strong and resilient structure that makes it available to be chosen as a tool in identification. It has been documented that the sinuses have the ability to withstand trauma and disasters even when extreme force is applied. The ability of the structure to remain intact even when exposed to high temperatures offers its use by the forensic experts. The characteristic convex shape of the frontal sinus shields it from destruction (Chaudhary & Singh, 2016).

The frontal sinuses are so safely located that even immense force of eight hundred to sixteen hundred foot pounds cannot alter the architectural anatomy and they stay unaffected within the skull (Wallis & Donald, 1988). The similarity in before and the after death radiographs can be utilized as a tool in the forensic anthropology (Ferreira-Silva et al., 2018).

Frontal sinus cephalometry is a procedure of choice for the purpose of personal identification in the situations of the disasters and the mass casualties. The importance of frontal air sinus in the anthropology has been observed since the early period of the twentieth century. This seemed possible because of the unique anatomy of frontal air sinuses in every person. (Çakur, Sumbullu, & Durna, (2011); Aydınlioğlu, Kavaklı, & Erdem, 2003; Sheriff, & Moideen, 2017; Demiralp, Cakmak, Aksoy, Bayrak, Orhan,& Demir, 2018;Tiwari, Bhovi, Jaju, Gupta, & Shrivastava, 2016).

The employed method of frontal sinus radiography is considered to be a simple yet effective one in identification of the unknown dead bodies (Silva, Franco,Saboia,

Rodrigues, & Gomes, 2015; Xavier, Terada, & da Silva, 2015; Buyuk, Simsek, & Karaman, 2018; Christensen & Hatch, 2018).

The anthropological use of frontal sinuses is of extreme value in conditions when there are skeletonized or mutilated bodies scattered all over and when the soft body tissue is even lost (Gibelli et al, 2018; Gopal & Vijayan, 2016; Soares et al., 2016; Nagaraj et al., 2017).

A case report documented that the dimensions present in the antemortem records matched with the postmortem radiographs. This helped the team in confirming the identification of the severely mutilated deceased body (Silva et al., 2015).

A study on Caucasian adults compared the frontal sinus size between the two groups. Age range for one group was 25 to 65 years and other with more than 65 years. It was documented that there was no age related size changes evident in the sample population (Cohen et al., 2018).

The distinctive features of the frontal sinuses make the technique of forensic radiography a reproducible technique. The radiographs were matched by first tracing and then superimposition technique. No two radiographs were identical to each other when matched. This testifies the unique structure of frontal air sinus in every individual, making frontal sinuses radiography an essential component of the forensic medicine (Nikam,Gadgil, Bhoosreddy, Shah, &Shirsekaret al., 2015; Stavrianos, Papadupoulos, Petalotis, 2013; Suman et al., 2016).

Research articles have documented that the comparison of the features between the antemortem and the postmortem radiographs can serve as a useful tool in identification of a person. There is a requirement that the characteristics and traits are known and recorded for every person. In case of investigation and personal identification, those anatomical features can be compared (Dasilva et al., 2019; Trant & Christensen 2018).

Scientific data has shown that there lies variability in the anatomical features of human skull and the face among people living in different regions around the world. The frontal air sinuses situated within the skull are also of variable shape and size among different ethnicities and diverse groups of individuals (House, Stringer, & Seals, 2017).

2.3 Anatomical variability of the frontal air sinuses

The difference in the size and shape of the frontal air sinus is due to the developmental variability (Duque & Casiano, 2005). Frontal sinus dimensions are even different in the twins. Out of 25 twin pairs, 17 were identical twins and eight were non- identical twins. None of the twins has the identical morphometric features. Although the dimensions were variable but they were not statistically significant (Chaiyasate, Baron, & Clement, 2007). A recently published article documented the variable pattern of anatomy in every individual. The authors attributed the differences in size and shape due to the variation in the pneumatization pattern. In 28.6 percent of the subjects, the sinus reached the medial wall of the orbit. In 48.6 percent of the participants, the growth of the frontal air sinuses reach the level of central region of the superior wall of the orbit, while in 20 percent of the study subjects, the frontal air sinus reach to the lateral wall of the orbit (Zhanna, Dzmitry, & Anzhelika 2019).

The dimensions of the left and the right frontal sinuses differ (Hacl et al., 2017). The dimensions of right frontal sinus are smaller as compared to the left frontal sinus. In females, the mean value for the right frontal sinus height was 22.95 mm and on the left side, it was 23.83 mm. The mean width in females measured 26.85 mm on the right side while on the left it measured 27.37 mm. The dimensions of width and height are more on the left side in comparison with the right side. In males, the mean height of the right frontal sinus was 23.82 mm and the value for the left side was 24.09. The mean width on the right side measured 27.65 mm and for the left side, it measured 28.11 mm (Tatlisumak et al., 2017).

The mean area in males was obtained to be 2118.27 mm² and the mean area in the females was smaller as shown by the documented value of 1654.79 mm² (Mohan & Dharman, 2019). The result was also in accordance with other study in which mean area in males was measured to be 1602.57mm² while in the females it was recorded as 1099.34 mm² (Verma et al., 2015).

There are research articles published in which the dimensions of the frontal air sinuses were reported to be bigger in dimensions for the right side as compared to the left

(Belaldavar, Kotrashetti, Hallikerimath, &Kale, 2014, & Eboh, Ogbeide, & Ivwighren, 2017).

2.4 Measuring technique of frontal air sinuses

There are two available methods, which can be employed in the measurements procedures of the frontal air sinuses. The procedures are designed to know the anatomical details that are specific to every person. One method is the tracing method and the other method employs the use of the digital measuring techniques (Buyuk et al., 2018; Gadekar et al., 2019; Rabelo et al., 2016; Soman, Sujatha, & Lingappa, 2016).

In the tracing method of frontal air sinuses, radiographs are first taken. The next step involves the development of the radiographic films followed by their drying. Once they are dried, then the outlines of the two sinuses are then drawn by the help of a pencil on the tracing paper (Nikam,Gadgil, Bhoosreddy, Shah, & Shirsekar, 2015; Suman et al., 2016; Verma, Nahar, Singh, Mathur, & Bhuvaneshwari, 2017).

Although measurements can be taken by both the methods, but in order to keep the readings error free, the digital method of measurements should be adopted while taking the measurements of the frontal air sinuses (Christensen & Hatch, 2018).

The digitalized methodology for finding various dimensions of the frontal air sinuses were adopted to make the readings more accurate and precise (Dhiman et al., 2015; Luu, Wang, Zhang & Mi, 2018; Nikolova et al., 2018; Said,Rossouw,Fishman,&Feng,2017; Soares et al., 2016;Watson, 2018).

2.5 Parameters used in radiography for measurement of frontal air sinuses

The uniqueness of the frontal sinuses anatomy is based on certain morphological and morphometric measurements. An article documented that there are certain parameters which can be used in identification of unknown bodies. In the study, Japanese skulls were observed for characteristic features specified for each body. There are certain parameters which when measured can be of extreme significance in identification of the unknown

bodies. The deviation of the midline septum can produce asymmetry of the frontal air sinuses present on the right and the left sides of the skull (Yoshino, Miyasaka, Sato, & Seta 1987).

2.5.1 Height of right frontal air sinuses

Various studies have reported different mean values for height of right frontal air sinus in the males and the females. The reported mean heights of the right frontal sinus are 1.12 cm, 1.6 cm, 1.75 cm and 19.3 mm in the males. The reported mean heights of the right frontal sinus in females are 1.19 cm, 1.4 cm, 1.47 cm and 17.5 mm (Chaudhary & Singh, 2016; Nethan, 2018; Soman et al., 2016; Verma, Mahima, & Patil, 2014).

2.5.2 Height of left frontal air sinuses

Various studies have reported different mean values for height of left frontal air sinus in the males and the females. The reported mean heights of the left frontal sinus are 1.50 cm, 1.85 cm, 1.9 cm and 20.9 mm in the males. The documented mean heights of the left frontal sinus in females are 1.32, 1.54 cm, 1.66 cm and 17.9 mm (Chaudhary & Singh, 2016; Nethan, 2018; Soman et al., 2016; Verma et al., 2014).

2.5.3 Width of right frontal air sinuses

Various studies have reported different mean values for right width in the males and the females. The mean widths of the right frontal sinus are 2.36 cm, 2.58 cm, 2.62 cm and 30.4 mm in the males. The reported mean widths of the right frontal sinus in females are 2.16 cm, 2.24 cm, 2.48 cm and 27.4 mm (Chaudhary & Singh, 2016; Nethan, 2018; Soman et al., 2016; Verma et al., 2014).

2.5.4 Width of left frontal air sinuses

Several studies have reported different mean values for left width in the males and the females. The mean widths of the left frontal sinus are 2.92 cm, 2.97 cm, 3.1 cm and 32.3 mm in the males. The reported mean widths of the left frontal sinus in females are 2.58 cm, 2.61 cm, 2.9 cm and 29.4 mm (Chaudhary & Singh, 2016; Nethan, 2018; Soman et al., 2016; Verma et al., 2014).

2.5.5 Area of right frontal air sinuses

Various studies have reported different mean values for right area in the males and the females. The mean areas of the right frontal sinus are 3.63 cm², 4.2 cm² and 4.52 cm² in the males. The reported mean areas of the right frontal sinus in females are 3.20 cm², 3.46 cm² and 3.64 cm² (Chaudhary & Singh, 2016; Nethan, 2018; Soman et al., 2016).

2.5.6 Area of left frontal air sinuses

Various studies have reported different mean values for left area in the males and the females. The mean areas of the left frontal sinus are 5 cm², 5.85 cm² and 6.22 cm² in the males. The reported mean area of the left frontal sinus in females are 3.89 cm², 4.29 cm² and 5.06 cm² (Chaudhary & Singh, 2016; Nethan, 2018; Soman et al., 2016).

2.6 Factors affecting the growth and development of frontal air sinuses

There are many factors which contribute to the development and growth of the frontal air sinuses. There can be genetic influence as well as effect of the climate on the expansion and extension of the two sinuses (Handa et al., 2015).

There are cases reported when on both the sides the development of the frontal air sinuses fails. The condition is known as bilateral aplasia. The bilateral agenesis of the frontal sinuses is documented in three to five percent of people. There are individuals in which

the aplasia is present on only one side. The percentage of unilateral aplasia was reported to be in range from one to seven percent (Duque & Casiano, 2005).

An interesting research article documented the variation of frontal sinus anatomy among different population groups. The frontal sinuses of the Egyptian mummies were smaller. The skulls of the mummies dated from 1567 BCE to 600 CE. The small size of the ancient frontal sinus within the skulls of the mummies was similar in size to the Egyptians of the modern era. This clearly demonstrates the genetic linkage and uniqueness of frontal sinuses in different races of humans (Márquez, Lawson, Mowbray, Delman, & Laitman, 2015).

A research article on the Canadian Eskimos has mentioned the absence of frontal air sinuses on both the sides in the 143 Eskimo skulls observed (Hanson & Owsley, 1980).

2.7 Sexual dimorphism of frontal air sinuses

Variability exists between the male and the female gender in terms of anatomical details (Benghiac, Moscalu, & Denisia, 2017; Camargo et al., 20017; Ezemagu, Anibeze, & Akpuaka, 2017; Mathur, Ahmed, Khorate, & Tripathi, 2013; Ramaswamy, & Khaitan, 2014; Tehranchi, Motamedian, Saedi, Kabiri, & Shidfar, 2017).

Studies from Iraq, Egypt and Turkey have suggested that variable gender features and anatomical details can help in forensic anthropology (Buyuk et al. 2018; Motawei, Wahba, Aboelmaaty; Tolba, 2016).

Human skulls display great variation between the male and the female gender. The mean area recorded in the males was 8.11 cm² while in the females, it was 6.35 cm² with a p value of 0.055. The mean width reported in the males was also greater in comparison to the females. The documented mean width in the males was 5.52 cm as compared to 4.65 cm in the females. Tehranchi et al., (2017) has also reported larger mean values for the height in males (2.97 cm) when matched with the mean value of the females (2.66 cm).

Benghiac et al. (2017) documented differences in the dimensions in between the two genders. The mean height in the males was reported 32.9 mm in contrast to 30.6 mm in the females. The mean width in the males was 8.3 and in females, 5.2 mm with the highly significant statistical significance (p value of 0.0001). Contrary to that few studies have documented non-significant dimensional differences between the two genders (Goyal, Acharya, Sattur, & Naikmasur, 2013).

A study on Eskimos has shown that the mean area of the male study participants was 2.87 cm² and in females, it was 2.07 cm² (Koertvelyessy, 1972).

The skulls of the males are bigger in size as compared to the females (Nateghian, Dashti, Faraji 2016). Other than that, the size of the orbit, palate, nasal aperture, zygomatic arch, the size of the mandible and the frontal sinus also differ (Kumar et al., 2015).

The upper section of the skull, especially the upper one-third region having frontal air sinuses plays a vital role in sexual dimorphism. This area serves as a tool in identification and hence considered a preferred region for forensic radiology (Cechova et al., 2019).

The radiographic findings can play a useful role in determining the male or female gender of the unknown persons and hence are vital tools in forensic anthropology. A Korean study on 119 cadavers revealed that there were significance variations observed in terms of the non-metric observations. The volume among the two sex groups was also noted to be different (Kim, et al., 2013).

A study documented that the mean dimensions are greater for the males as compared to the females. The mean height in males was recorded to be 20.86 mm and for the females, the mean height was observed to be 15.35 mm. The mean width in males was 61.66 mm while for females it was recorded to be 36.66 mm (Verma et al., 2017).

An Indian study has mentioned bigger dimensions for the males as compared to the females group of participants. It was documented that the right mean height in the males was 3.43 cm versus 3.03 cm in the females. The left frontal air sinus height in the males was 3.47 cm and in the females, it was 3.15 cm. The mean right sinus width was measured 2.85 cm in the males and in the female gender it was 2.69 cm. The mean left sinus width was documented to be 3.29 cm in the males and 3.01 cm in the females. Although the dimensions are greater for the males but they were not statistically significant (Sheikh, Ashwinirani, Suragimath, & Kumar, 2018).

A research article documented that the mean height in females was measured to be 25.94 mm and in males, the mean height was 31.13 mm. In the males, the mean width was 51.48 mm as compared to 42.38 mm in females (Verma et al., 2015).

Another research demonstrated that out of 130 study participants, 80 percent were correctly identified using the anatomical features of the frontal sinuses (Choi, Duailibi-Neto, Beaini, da Silva, & Chilvarquer, 2018).

A research on the South Indian population documented that the greater mean dimensions were noted for the area of frontal sinus in the males participants of the research as compared to the females. The mean area in the males was 1041.8 mm² as compared to the value of 783.3 mm² in the females (Verma et al., 2014).

A study was conducted on the Romanian people between the age groups of eighteen to sixty five years. The right and left frontal sinus height and width were measured. It was reported in the results that the right frontal sinus height was helpful in predicting the gender correctly in sixty percent of males as well as sixty percent of females. The left sinus height predicted the correct gender in 53.3 percent of females and for the males, the percentage was forty (Benghiac et al., 2017).

2.8 Comparison of antemortem radiographs with the postmortem radiographs

The unique morphology of the frontal air sinuses that is specific for every person, makes them a tool of choice for the forensic investigation. A Brazilian research article, documented a case report in which forensic investigation was done on the skeletonized body found in the forest of Brazil. Radiography was performed. The post-surgical antemortem radiographs were obtained from the saved files in the data. The anatomical features of frontal sinuses of the postmortem radiograph were matched with the antemortem radiograph of the victim obtained from the health records. (Ferreira-Silva et al., 2018).

Another study also documented similar results and mentioned about the anthropological significance of the frontal air sinus unique anatomy in the forensic radiography. A skull that was found on the highway was radiographed by the forensic team experts. Frontal air sinuses were found to have similar morphology in terms of the size, shape, location of lobes, location and deviation of the medium septum (Prado et al., 2016).

The unique nature of frontal air sinus in people living in different regions of the world is proved by the above mentioned research and the statistics published in various reputable research journals world over. There is a need to do a study that can help document the anatomical dimensions and their associated variations between the males and females of different ethnicities of Pakistani population. This will facilitate the forensic science department as well as the anthropologists.

METHODOLOGY

3.1 Research Design

This is a cross sectional, descriptive type of a study

3.2 Ethical approval

- The study was conducted after acquiring approval from the
 - a. Institutional Review Board of Jinnah Postgraduate Medical Center
 - b. Ethics Review Committee of Bahria University Medical and Dental College
- The study participants were explained the objectives and the rationale of the study prior obtaining the informed consent signed forms
- The informed consent forms were both in Urdu and English for better understanding of the subjects participating in the research
- The risks and benefits were explained in detail to the study participants
- The literate subjects signed the consent forms
- The illiterate subjects used thumb prints
- The participants were allowed to leave the study in case they did not want to be the part of the research at any point of time
- Confidentiality of the collected data was maintained
- The research was done according to the declaration of Helsinki

3.3 Setting

- The place of the research was Jinnah Postgraduate Medical Center
- The participants were recruited from the room number 2 of the radiology ward

3.4 Inclusion criteria

Males and females, free of paranasal sinus diseases between the ages 20 – 50 years

3.5 Exclusion criteria

- Males and females of age below 20 and above 50
- Patients with previous paranasal sinus surgery
- Patients with disease of paranasal sinus
- Pregnancy
- Patients with head trauma/injury

3.6 Duration of study

(a) Individual study period: 40 minutes

(b) Total period of study: 6 months

3.7 Sample size estimation

The sample size was estimated using the method of comparing proportions utilizing OpenEpi, Version 3, open source calculator–S Proper. The sample size was based on population prevalence and was calculated using www.openepi.com. The prevalence of population was 50 %. The sample size was calculated with 5% margin of error and 95% confidence interval. Minimum sample size calculated was $N= 214$, with $n_1=54$, $n_2= 54$, $n_3=53$ and $n_4= 53$. However, this study included 236 subjects with 59 in each group.

3.8 Sampling technique

The technique used in the present study research was non-probability convenient random sampling. The subjects were selected according to the inclusion criteria. Equal number of members from the four ethnic groups were included to maintain the uniformity.

The frontal sinuses of the participants were radiographed by the X-ray radiological technique. The radiographic view used for frontal sinus imaging was Water's view.

The mean age of the subjects under study was 35.14 ± 8.68 years.

3.9 Human subjects & consent

- The study involved human subjects
- The informed consent was obtained from the study participants after explaining the benefits and the associated risks of the study

3.10 Materials (Drugs / Chemicals / Proforma / Questionnaire / other requirements)

1. Questionnaire

In the questionnaire details of demographic data were filled for each subject

2. Radiographic requirements

- The radiography was performed using STEPHNEX apparatus
- Water's view (Occipito-mental view) radiographs were exposed
- Each radiograph measured 10×12 cm in size
- The distance was of 36 cm from source to film using an exposure of 125 KVP at 630 mA.
- The radiographs were saved in high resolution JPEG file and were measured by the software RadiAnt DICOM Viewer.

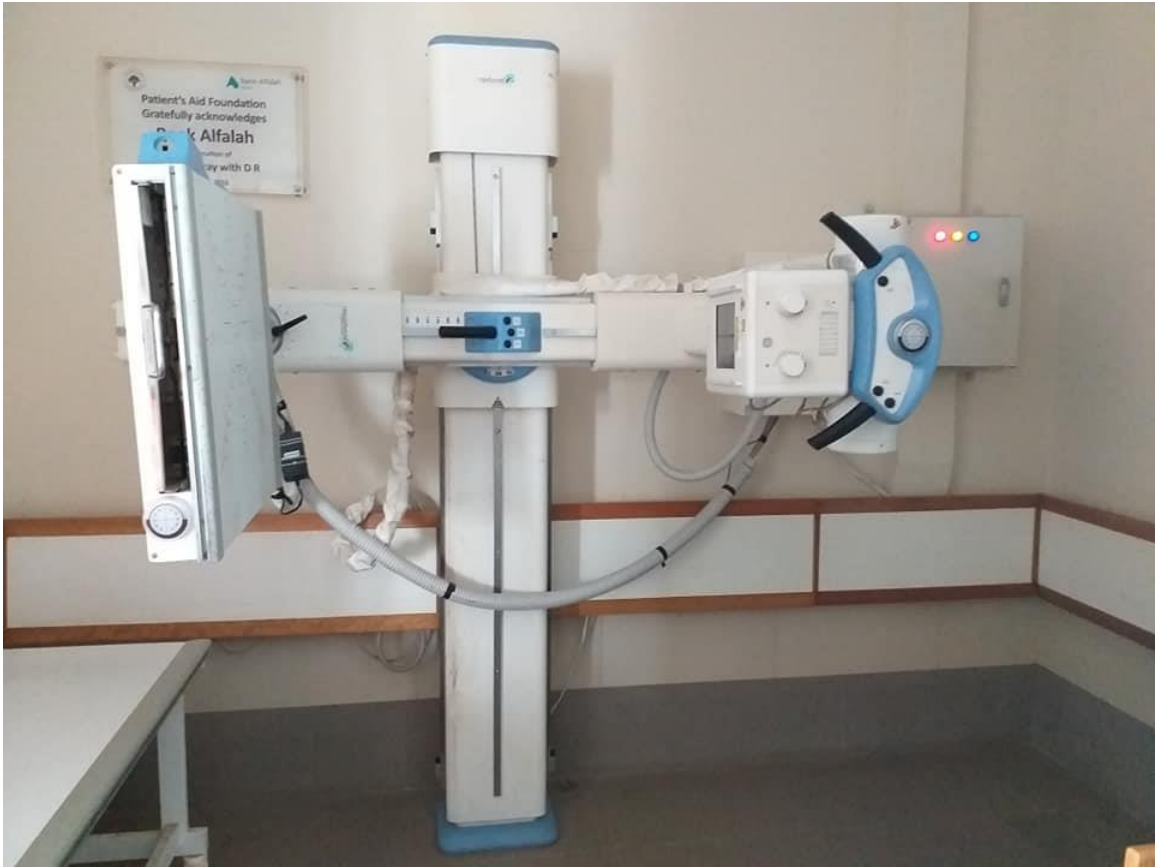

Figure 11: STEPHNEX machine used during research at JPMC, radiology ward, room number 2.

3. Proformas

- The proformas were filled for each individual
- Each proforma was assigned a code number
- The following variables of the right frontal sinus were noted in the proforma
 - Width
 - Height
 - Area
- The following variables of the left frontal sinus were noted in the proforma
 - Width
 - Height
 - Area

3.11 Lab. Parameters

The parameters observed during the study were as follows

- Width of the right frontal sinus
- Width of the left frontal sinus
- Height of the right frontal sinus
- Height of the left frontal sinus
- Area of the right frontal sinus
- Area of the left frontal sinus
- The linear measurements of width and height were expressed in cm
- The area unit used was cm^2

3.12 Methodology/ Protocol

1. Recruitment of subjects

- The study subjects were selected from the JPMC radiology ward. The room 2 of the radiology ward is used for PNS (paranasal sinus), spine and chest radiography. The subjects that came for spine and the chest radiography were asked for giving consent for being a part of the research
- The questionnaires were filled by those who willingly consented. The demographic data was entered and those participants were selected who fulfilled the inclusion criteria
- The imaging of the frontal air sinuses was done by Water's view radiograph

2. Division of groups

- 216 patients were included in the study
- They were further divided into 4 ethnic groups
 - Sindhi
 - Pathan
 - Punjabi
 - Urdu speaking
- Each ethnic group had 54 members
- The four ethnic groups were further divided into 2 sub-groups of male and female genders
- The ethnic groups with subgroups were as follows
 - ✚ Sindhi ethnic group
 - Males (27 members)
 - Females (27 members)
 - ✚ Pathan ethnic group
 - Males (27 members)
 - Females (27 members)

✚ Punjabi ethnic group

Males (27 members)

Females (27 members)

✚ Urdu speaking ethnic group

Males (27 members)

Females (27 members)

3. Methodology for obtaining Water's view radiographs

- Each subject was asked to stand erect while facing the detector
- The chin was raised so that the meato-mandibular line become perpendicular to the receptor
- X-ray beam was horizontal at a point that was one inch above the external occipital protuberance
- X-ray beam was perpendicular to the radiographic plate
- X-ray beam was at an angle of 45 degrees to the orbito-meatal line
- The radiographs were saved in the DICOM (Digital Imaging Communication in Medicine) file format
- The measurements were done using the RadiAnt DICOM software (Tatlisumak et al., 2017).



Figure 12: Positioning of the research subject for the Water's view radiograph

4. Methodology for frontal sinuses measurements

- The parameters were recorded according to the method used by Ribeiro, (Ribeiro & de Andrade, 2000).
- Base line A was drawn on the upper limit of both the orbits
- The highest point of the right frontal sinus was marked as B
- A perpendicular line C was drawn from the highest point of right frontal sinus to the base line A
- The perpendicular line C was considered as the height of the right frontal sinus
- The highest point of the left frontal sinus was marked as D
- A perpendicular line E was drawn from the highest point of left frontal sinus to the base line A
- The perpendicular line E was considered as the height of the left frontal sinus
- Line passing at the most lateral point of right frontal sinus was marked as F
- A perpendicular line G represents maximum distance drawn from the most lateral point of right frontal sinus to the midline septum
- The perpendicular line G was considered as the width of the right frontal sinus
- Line passing at the most lateral point of left frontal sinus was marked as H
- A perpendicular line I represents maximum distance drawn from the most lateral point of left frontal sinus to the midline septum
- The perpendicular line I was considered as the width of the left frontal sinus
- Right area was calculated as a product of right height and right width
- Left area was calculated as a product of left height and left width

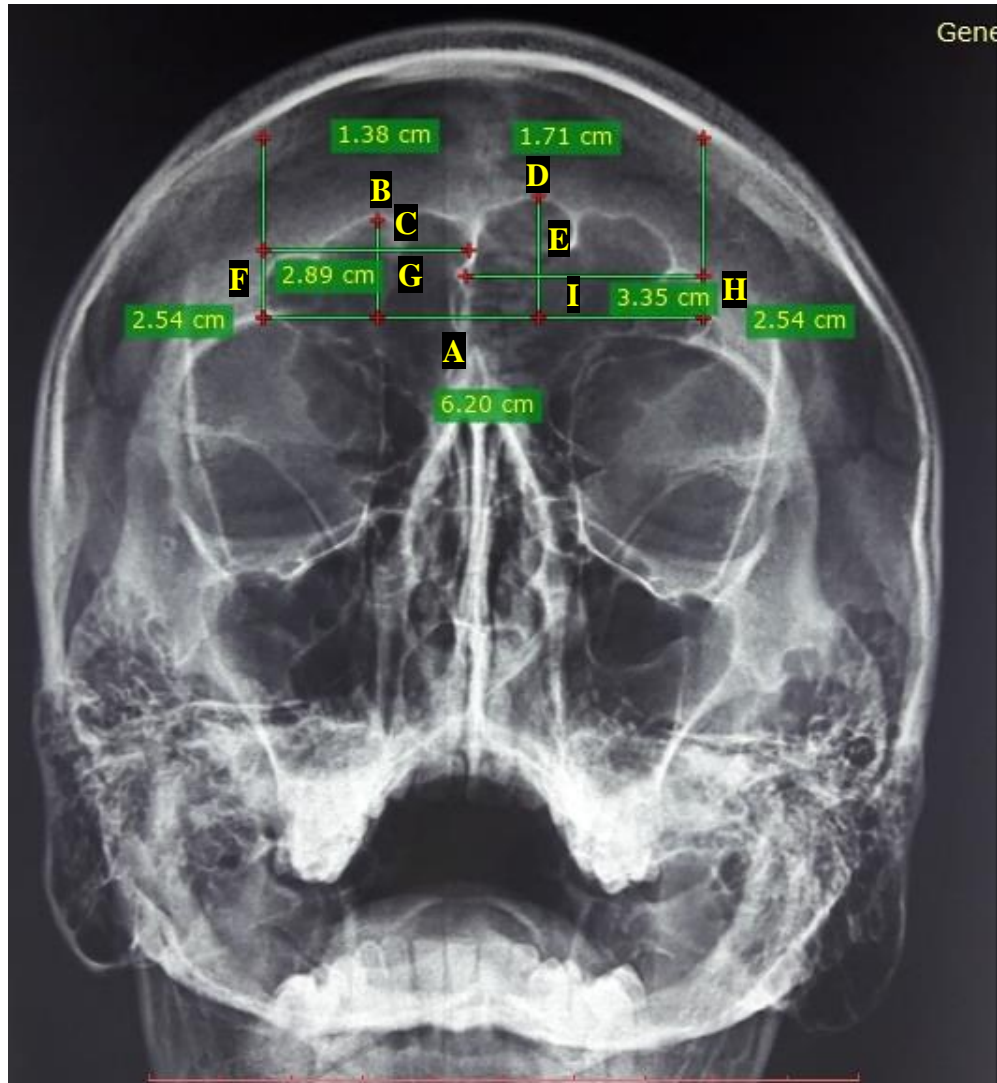
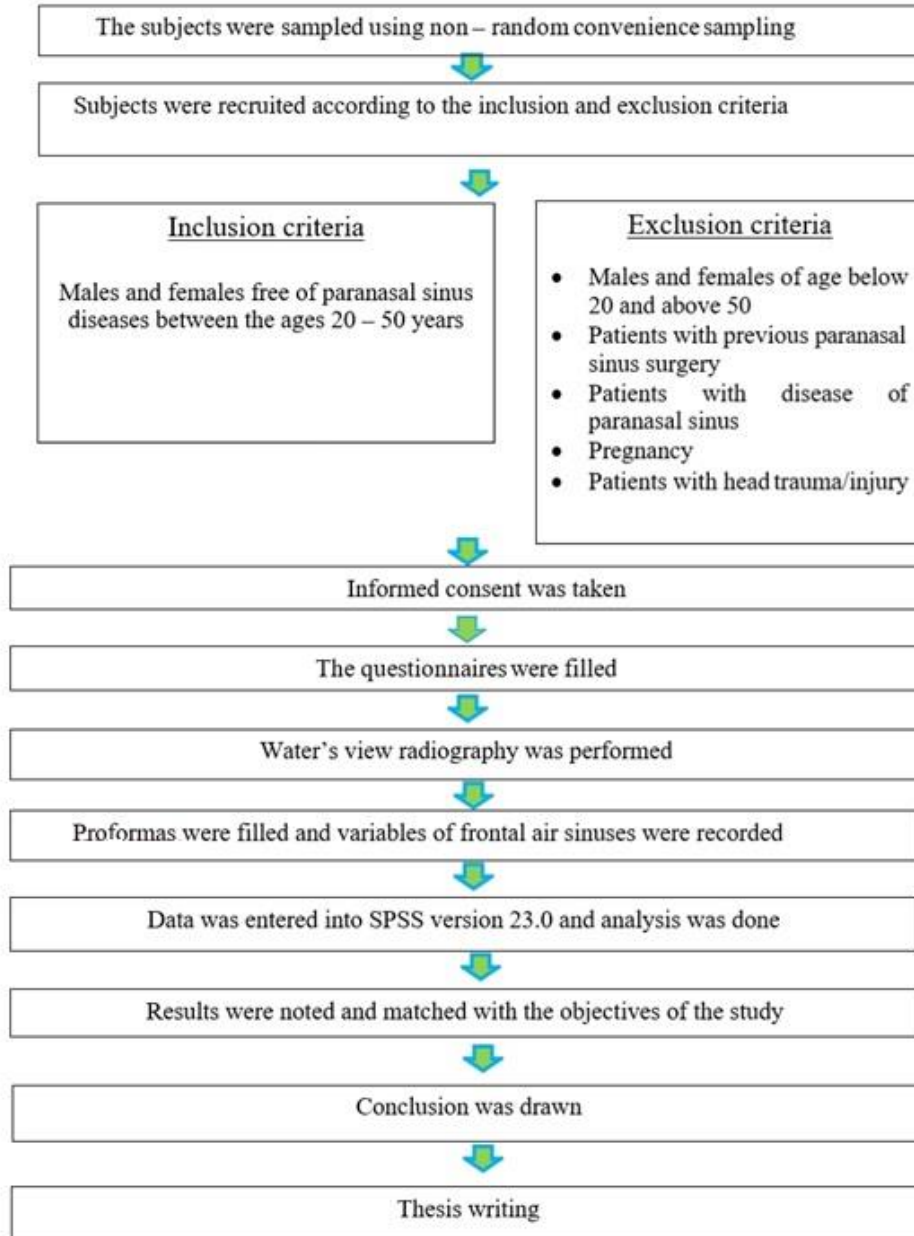


Figure 13: Methodology for taking measurements

- A- Base line
- B- Highest point of the right sinus from the base line,
- C- Height of the right sinus
- D- Highest point of the left sinus from the base line,
- E- Height of the left sinus
- F- Line passing at the most lateral point of right frontal sinus,
- G- Maximum distance in between line F and the midline septum (right width)
- H- Line passing at the most lateral point of left frontal sinus,
- I- Maximum distance in between line H and the midline septum (left width)

3.13 Algorithm of the study



3.14 Statistical Analysis

- SPSS version 23.0 was used for the statistical analysis
- Qualitative data was measured as frequency and percentages
- The continuous data was reported as mean \pm SD
- Histogram with normal curve was made for visualizing the data.
- The data was normally distributed therefore Independent Samples t - Test was used for comparison measured between the two genders
- The one-way analysis of variance (ANOVA) was used to determine statistically significant between the means of independent (unrelated ethnic) groups
- The results were regarded as significant when the *p value was ≤ 0.05*
- The results were regarded as highly significant when the *p value was ≤ 0.001*

RESULTS

All the study participants were observed for the morphometric details of the frontal air sinuses. The height, width and area was calculated for both the frontal sinuses.

4.1 Gender wise comparison of right and left frontal sinus height

Mean height of the right and left frontal sinuses in males were $2.30 \text{ cm} \pm 0.70$ and $2.63 \text{ cm} \pm 0.66$ respectively. In females, these heights were $1.97 \text{ cm} \pm 0.62$ and $2.30 \text{ cm} \pm 0.63$ respectively. Statistically, males have significantly higher height than females on both the sides (Table 1, Figure 14).

4.2 Gender wise comparison of right and left frontal sinus width

Mean width of the right and left frontal sinuses in males were $2.72 \text{ cm} \pm 0.65$ and $3.53 \text{ cm} \pm 0.65$ respectively. In females, these widths were $2.41 \text{ cm} \pm 0.60$ and $3.21 \text{ cm} \pm 0.61$ respectively. Statistically, males have significantly higher width than females on both the sides (Table 2).

4.3 Gender wise comparison of right and left frontal sinus area

Mean area of the right and left frontal sinuses in males were $6.58 \text{ cm}^2 \pm 2.89$ and $9.66 \text{ cm}^2 \pm 3.60$ respectively. In females, these areas were $5.05 \text{ cm}^2 \pm 2.30$ and $7.70 \text{ cm}^2 \pm 3.01$ respectively. Statistically, males have significantly higher area than females on both the sides (Table 3, Figure 15).

4.4 Ethnicity wise comparison of mean height of right frontal sinus among the male groups

Mean height of right frontal sinuses in Sindhi, Pathan, Punjabi and Urdu speaking males were 1.32 cm \pm 0.16, 2.87 cm \pm 0.47, 2.59 cm \pm 0.29 and 2.40 cm \pm 0.51 respectively. Statistically highly significant differences were present amongst all the ethnic groups (Table 4, Figure 16).

4.5 Ethnicity wise comparison of mean height of left frontal sinus among the male groups

Mean height of left frontal sinuses in Sindhi, Pathan, Punjabi and Urdu speaking males were 1.65 cm \pm 0.20, 3.19 cm \pm 0.23, 2.91 cm \pm 0.27 and 2.76 cm \pm 0.44 respectively. Statistically highly significant differences were present amongst all the ethnic groups (Table 5, Figure 16).

4.6 Ethnicity wise comparison of mean width of right frontal sinus among the male groups

Mean width of right frontal sinuses in Sindhi, Pathan, Punjabi and Urdu speaking males were 1.71 cm \pm 0.19, 3.26 cm \pm 0.32, 2.99 cm \pm 0.24 and 2.90 cm \pm 0.29 respectively. Statistically highly significant differences were present amongst all the ethnic groups (Table 6).

4.7 Ethnicity wise comparison of mean width of left frontal sinus among the male groups

Mean width of left frontal sinuses in Sindhi, Pathan, Punjabi and Urdu speaking males were $2.55 \text{ cm} \pm 0.22$, $4.11 \text{ cm} \pm 0.29$, $3.83 \text{ cm} \pm 0.27$ and $3.65 \text{ cm} \pm 0.32$ respectively. Statistically highly significant differences were present amongst all the ethnic groups (Table 7).

4.8 Ethnicity wise comparison of mean area of right frontal sinus among the male groups

Mean area of right frontal sinuses in Sindhi, Pathan, Punjabi and Urdu speaking males were $2.28 \text{ cm}^2 \pm 0.43$, $9.35 \text{ cm}^2 \pm 1.63$, $7.76 \text{ cm}^2 \pm 1.12$ and $6.91 \text{ cm}^2 \pm 1.26$ respectively. Statistically highly significant differences were present amongst all the ethnic groups (Table 8).

4.9 Ethnicity wise comparison of mean area of left frontal sinus among the male groups

Mean area of left frontal sinuses in Sindhi, Pathan, Punjabi and Urdu speaking males were $4.21 \text{ cm}^2 \pm 0.57$, $13.15 \text{ cm}^2 \pm 1.28$, $11.18 \text{ cm}^2 \pm 1.29$ and $10.11 \text{ cm}^2 \pm 1.94$ respectively. Statistically highly significant differences were present amongst all the ethnic groups (Table 9, Figure 17).

4.10 Ethnicity wise comparison of mean height of right frontal sinus among the female groups

Mean height of right frontal sinuses in Sindhi, Pathan, Punjabi and Urdu speaking females were 1.05 cm \pm 0.21, 2.53 cm \pm 0.42, 2.18 cm \pm 0.20 and 2.12 cm \pm 0.28 respectively. Statistically highly significant differences were present amongst all the ethnic groups (Table 10, Figure 18).

4.11 Ethnicity wise comparison of mean height of left frontal sinus among the female groups

Mean height of left frontal sinuses in Sindhi, Pathan, Punjabi and Urdu speaking females were 1.38 cm \pm 0.17, 2.85 cm \pm 0.32, 2.52 cm \pm 0.25 and 2.45 cm \pm 0.43 respectively. Statistically highly significant differences were present amongst all the ethnic groups (Table 11, Figure 18).

4.12 Ethnicity wise comparison of mean width of right frontal sinus among the female groups

Mean width of right frontal sinuses in Sindhi, Pathan, Punjabi and Urdu speaking females were 1.50 cm \pm 0.27, 2.93 cm \pm 0.18, 2.59 cm \pm 0.22 and 2.62 cm \pm 0.39 respectively. Statistically highly significant differences were present amongst all the ethnic groups (Table 12).

4.13 Ethnicity wise comparison of mean width of left frontal sinus among the female groups

Mean width of left frontal sinuses in Sindhi, Pathan, Punjabi and Urdu speaking females were $2.29 \text{ cm} \pm 0.23$, $3.76 \text{ cm} \pm 0.24$, $3.42 \text{ cm} \pm 0.25$ and $3.37 \text{ cm} \pm 0.32$ respectively. Statistically highly significant differences were present amongst all the ethnic groups (Table 13, Figure 19).

4.14 Ethnicity wise comparison of mean area of right frontal sinus among the female groups

Mean area of right frontal sinuses in Sindhi, Pathan, Punjabi and Urdu speaking females were $1.58 \text{ cm}^2 \pm 0.42$, $7.39 \text{ cm}^2 \pm 1.12$, $5.65 \text{ cm}^2 \pm 0.60$ and $5.58 \text{ cm}^2 \pm 1.07$ respectively. Statistically highly significant differences were present amongst all the ethnic groups (Table 14).

4.15 Ethnicity wise comparison of mean area of left frontal sinus among the female groups

Mean area of left frontal sinuses in Sindhi, Pathan, Punjabi and Urdu speaking females were $3.18 \text{ cm}^2 \pm 0.58$, $10.72 \text{ cm}^2 \pm 1.40$, $8.63 \text{ cm}^2 \pm 1.02$ and $8.25 \text{ cm}^2 \pm 1.47$ respectively. Statistically highly significant differences were present amongst all the ethnic groups (Table 15).

Table 1
Gender wise comparison of right and left frontal sinus height
N= 216

Parameter	Gender	n	Mean ± SD	p value
RT HEIGHT (cm)	Male	108	2.30 ± 0.70	0.000**
	Female	108	1.97 ± 0.62	
LT HEIGHT (cm)	Male	108	2.63 ± 0.66	0.000**
	Female	108	2.30 ± 0.63	

RT HEIGHT: Right frontal sinus height

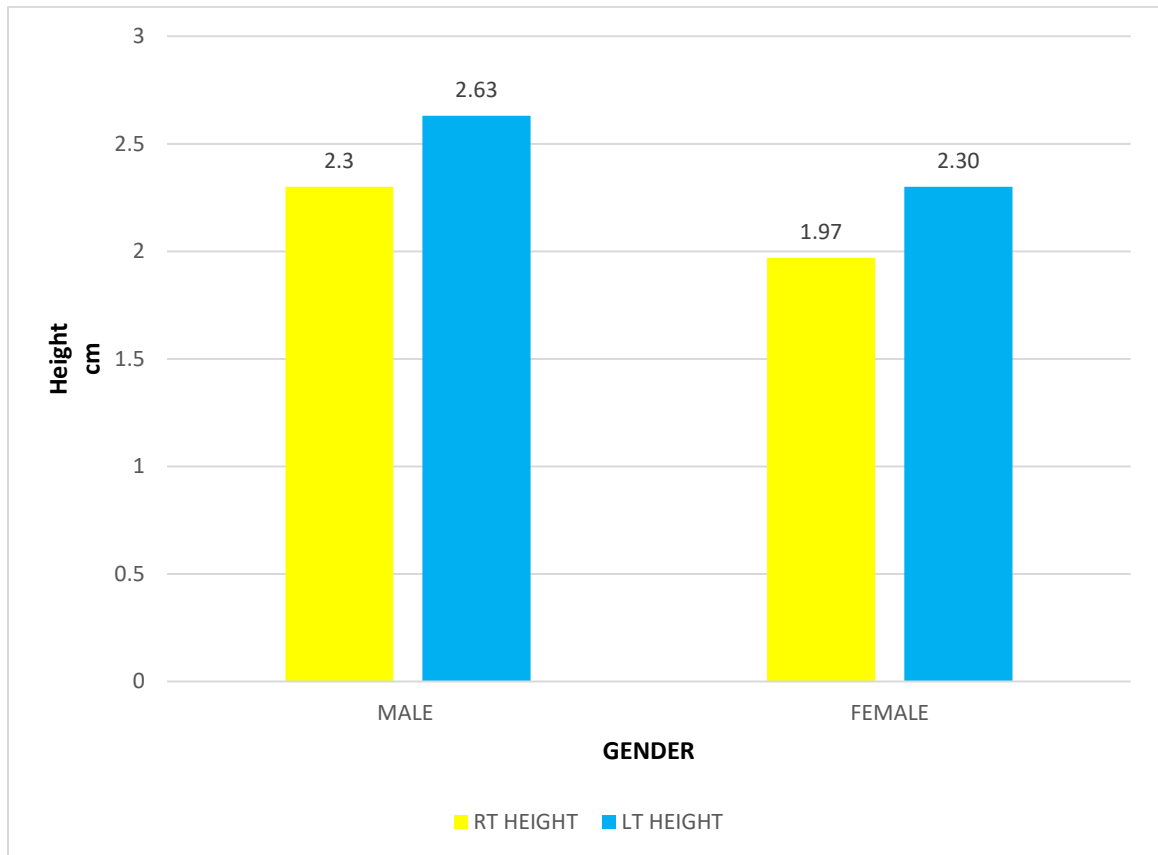
LT HEIGHT: Left frontal sinus height

p value significant $\leq 0.05^*$, highly significant: $\leq 0.001^{**}$

Test applied: Independent Samples t - Test

Figure 14

Gender wise comparison of right and left frontal sinus height



RT HEIGHT: Right height

LT HEIGHT: Left height

cm: centimeter

Table 2

Gender wise comparison of right and left frontal sinus width

N= 216

Parameter	Gender	n	Mean \pm SD	p value
RT WIDTH (cm)	Male	108	2.72 \pm 0.65	0.000**
	Female	108	2.41 \pm 0.60	
LT WIDTH (cm)	Male	108	3.53 \pm 0.65	0.000**
	Female	108	3.21 \pm 0.61	

RTWIDTH: Right frontal sinus width

LTWIDTH: Left frontal sinus width

p value significant \leq 0.05*, highly significant: \leq 0.001**

Test applied: Independent Samples t - Test

Table 3

Gender wise comparison of right and left frontal sinus area

N= 216

Parameter	Gender	n	Mean \pm SD	p value
RT AREA (cm ²)	Male	108	6.58 \pm 2.89	0.000**
	Female	108	5.05 \pm 2.30	
LT AREA (cm ²)	Male	108	9.66 \pm 3.60	0.000**
	Female	108	7.70 \pm 3.01	

RTAREA: Right frontal sinus area

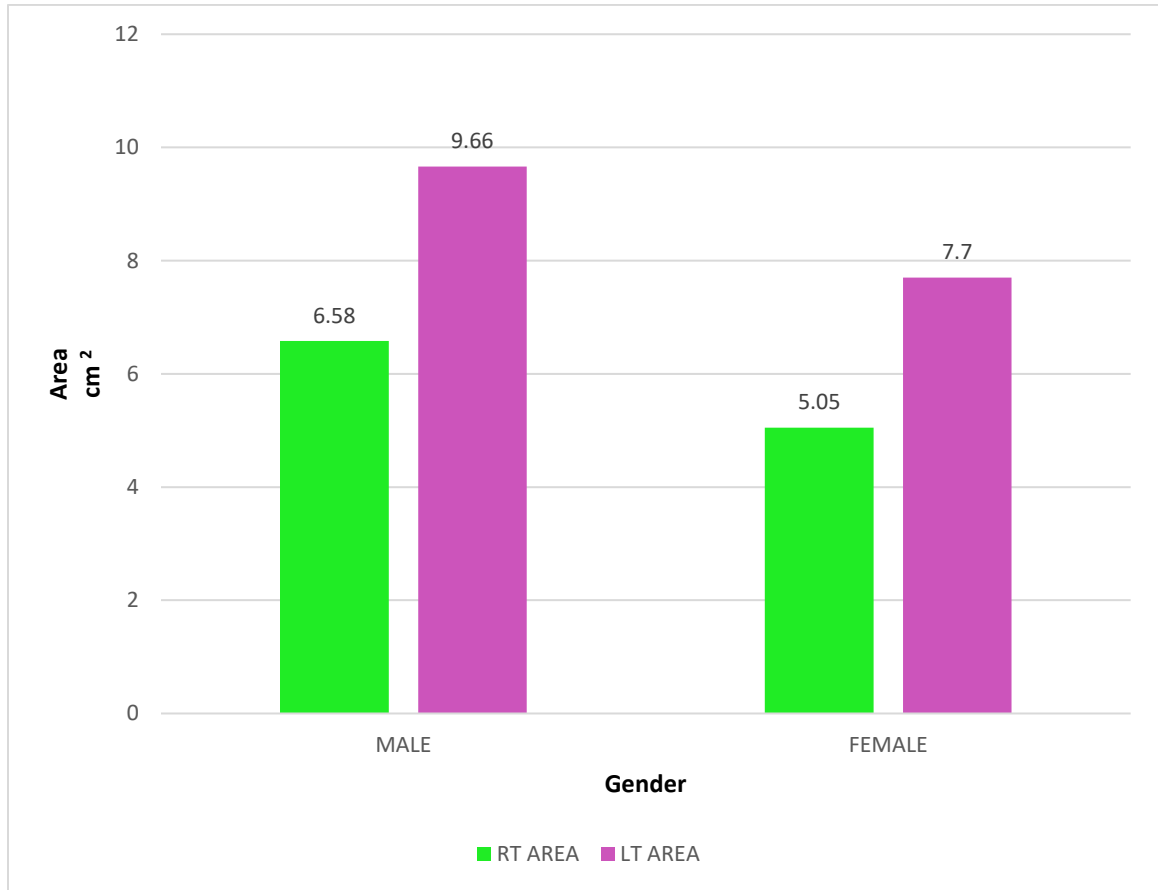
LTAREA: Left frontal sinus area

p value significant $\leq 0.05^*$, highly significant: $\leq 0.001^{**}$

Test applied: Independent Samples t - Test

Figure 15

Gender wise comparison of right and left frontal sinus mean area



RT AREA: Right area

LT AREA: Left area

cm²: Centimeter square

Table 4

Ethnicity wise comparison of mean height of right frontal sinus among the male groups

N= 108

Parameter	Ethnicity	n	Mean ± SD	p value
RT HEIGHT MALE (cm)	Sindhi	27	1.32 ± 0.16	0.000**
	Pathan	27	2.87 ± 0.47	
	Punjabi	27	2.59 ± 0.29	
	Urdu speaking	27	2.40 ± 0.51	

RTHEIGHT MALE: Right height male

p value significant $\leq 0.05^*$, highly significant: $\leq 0.001^{**}$

Test applied: One-Way ANOVA

Table 5

Ethnicity wise comparison of mean height of left frontal sinus among the male groups
N=108

Parameter	Ethnicity	n	Mean ± SD	p value
LT HEIGHT MALE (cm)	Sindhi	27	1.65 ± 0.20	0.000**
	Pathan	27	3.19 ± 0.23	
	Punjabi	27	2.91 ± 0.27	
	Urdu speaking	27	2.76 ± 0.44	

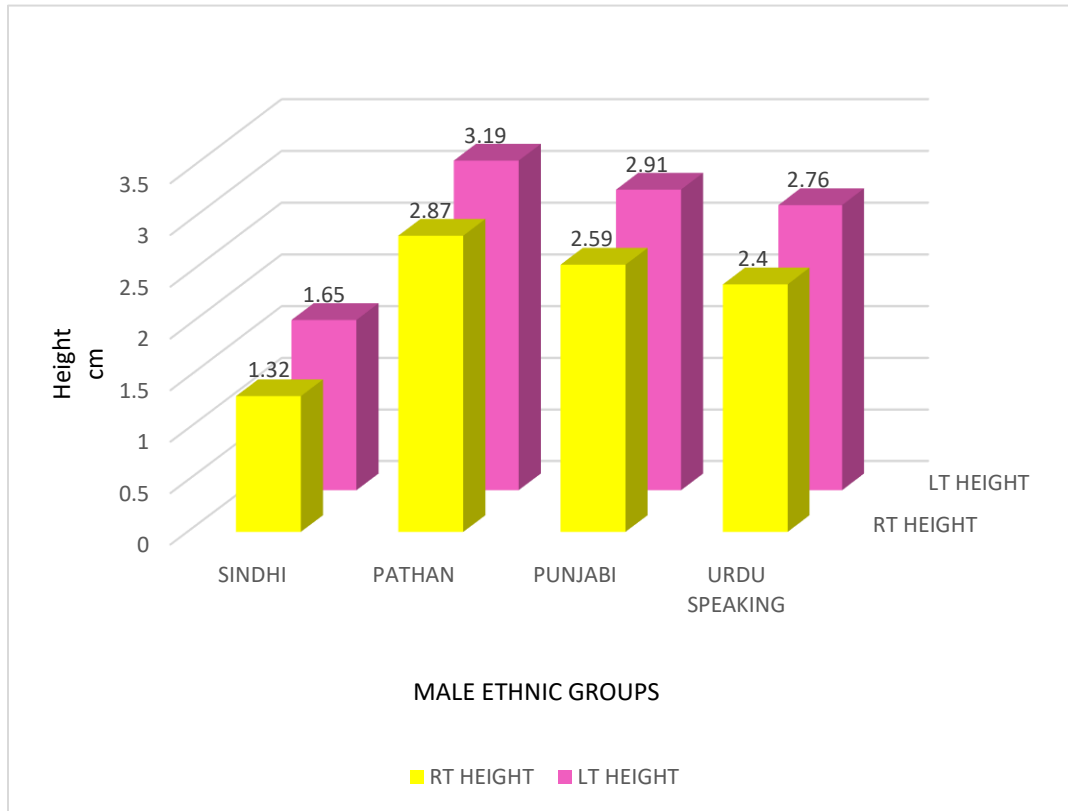LTHEIGHT MALE: Left height male

p value significant $\leq 0.05^*$, highly significant: $\leq 0.001^{**}$

Test applied: One-Way ANOVA

Figure 16

Ethnicity wise comparison of mean heights of right and left frontal sinuses among the male groups



RT HEIGHT: Right height

LT HEIGHT: Left height

cm: Centimeter

Table 6

Ethnicity wise comparison of mean width of right frontal sinus among the male groups

N= 108

Parameter	Ethnicity	n	Mean \pm SD	p value
RT WIDTH MALE (cm)	Sindhi	27	1.71 \pm 0.19	0.000**
	Pathan	27	3.26 \pm 0.32	
	Punjabi	27	2.99 \pm 0.24	
	Urdu speaking	27	2.90 \pm 0.29	

RT WIDTH MALE: Right width male

p value significant $\leq 0.05^*$, highly significant: $\leq 0.001^{**}$

Test applied: One-Way ANOVA

Table 7

Ethnicity wise comparison of mean width of left frontal sinus among the male groups

N= 108

Parameter	Ethnicity	n	Mean \pm SD	p value
LT WIDTH MALE (cm)	Sindhi	27	2.55 \pm 0.22	0.000**
	Pathan	27	4.11 \pm 0.29	
	Punjabi	27	3.83 \pm 0.27	
	Urdu speaking	27	3.65 \pm 0.32	

LT WIDTH MALE: Left width male

p value significant $\leq 0.05^*$, highly significant: $\leq 0.001^{**}$

Test applied: One-Way ANOVA

Table 8

Ethnicity wise comparison of mean area of right frontal sinus among the male groups

N= 108

Parameter	Ethnicity	n	Mean \pm SD	p value
RT AREA MALE (cm ²)	Sindhi	27	2.28 \pm 0.43	0.000**
	Pathan	27	9.35 \pm 1.63	
	Punjabi	27	7.76 \pm 1.12	
	Urdu speaking	27	6.91 \pm 1.26	

RT AREA MALE: Right area male

p value significant $\leq 0.05^*$, highly significant: $\leq 0.001^{**}$

Test applied: One-Way ANOVA

Table 9

Ethnicity wise comparison of mean area of left frontal sinus among the male groups

N= 108

Parameter	Ethnicity	n	Mean ± SD	p value
LT AREA MALE (cm ²)	Sindhi	27	4.21 ± 0.57	0.000**
	Pathan	27	13.15 ± 1.28	
	Punjabi	27	11.18 ± 1.29	
	Urdu speaking	27	10.11 ± 1.94	

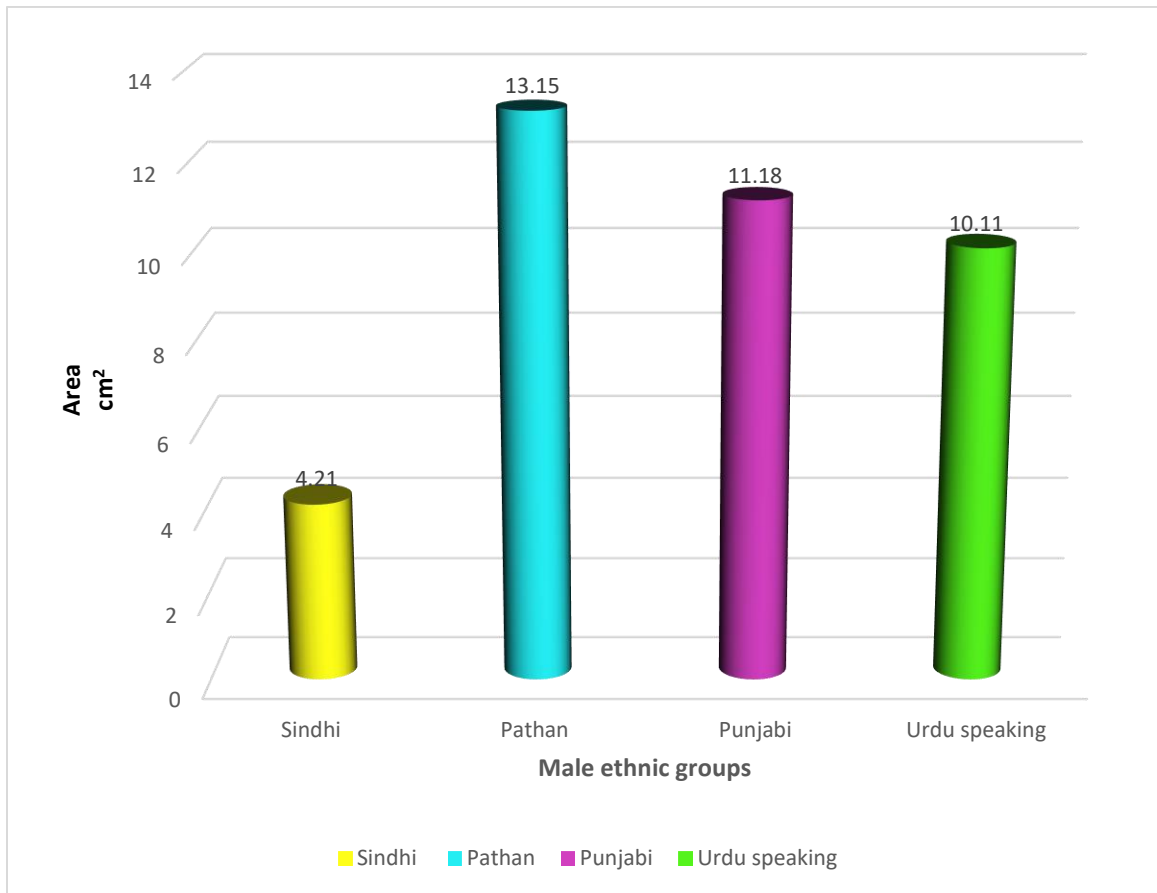
LT AREA MALE: Right area male

p value significant $\leq 0.05^*$, highly significant: $\leq 0.001^{**}$

Test applied: One-Way ANOVA

Figure 17

Ethnicity wise comparison of mean area of left frontal sinus among the male groups



cm²: centimeter square

Table 10

Ethnicity wise comparison of mean height of right frontal sinus among the female groups

N= 108

Parameter	Ethnicity	n	Mean \pm SD	p value
RTHEIGHT FEMALE (cm)	Sindhi	27	1.05 \pm 0.21	0.000**
	Pathan	27	2.53 \pm 0.42	
	Punjabi	27	2.18 \pm 0.20	
	Urdu speaking	27	2.12 \pm 0.28	

RTHEIGHT FEMALE: Right height female

p value significant \leq 0.05*, highly significant: \leq 0.001**

Test used: One-Way ANOVA

Table 11

Ethnicity wise comparison of mean height of left frontal sinus among the female groups

N= 108

Parameter	Ethnicity	n	Mean \pm SD	p value
LT HEIGHT FEMALE (cm)	Sindhi	27	1.38 \pm 0.17	0.000**
	Pathan	27	2.85 \pm 0.32	
	Punjabi	27	2.52 \pm 0.25	
	Urdu speaking	27	2.45 \pm 0.43	

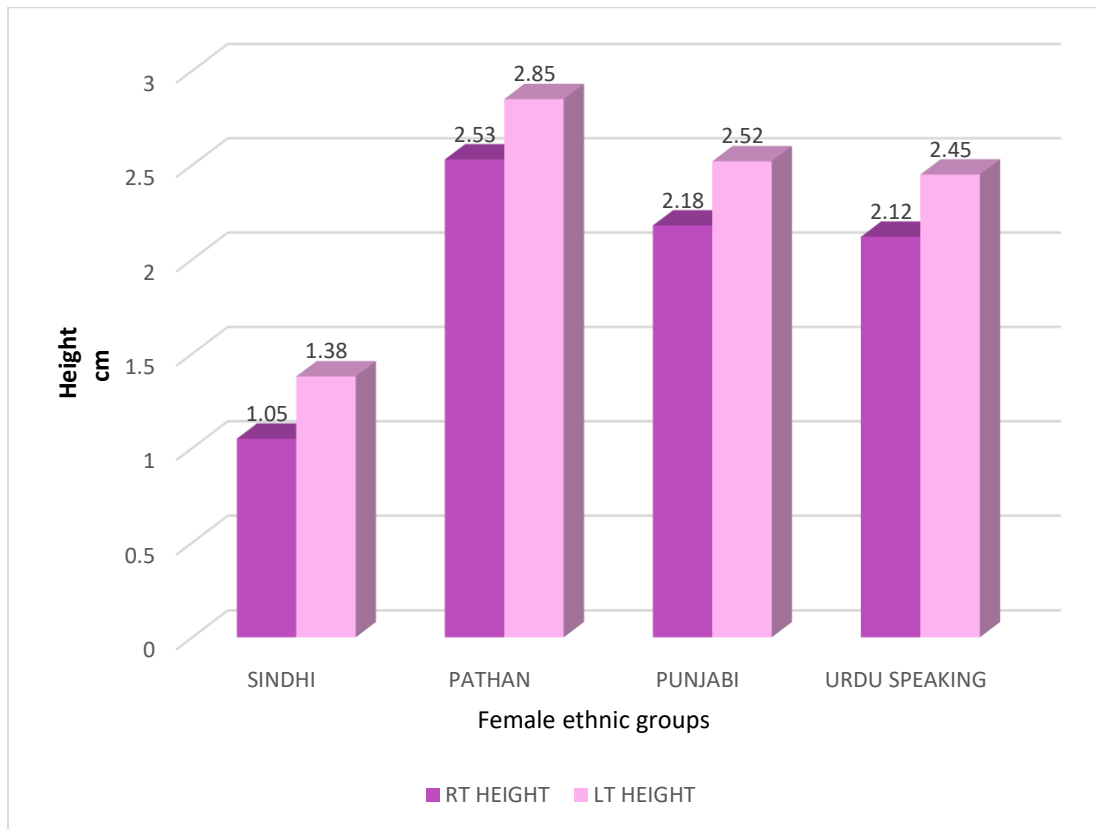
LTHEIGHT FEMALE: Left height female

p value significant $\leq 0.05^*$, highly significant: $\leq 0.001^{**}$

Test used: One-Way ANOVA

Figure 18

Ethnicity wise comparison of mean heights of right and left frontal sinuses among the female groups



RT HEIGHT: Right height

LT HEIGHT: Left height

Cm: centimeter

Table 12

Ethnicity wise comparison of mean width of right frontal sinus among the female groups

N= 108

Parameter	Ethnicity	n	Mean \pm SD	p value
RT WIDTH FEMALE (cm)	Sindhi	27	1.50 \pm 0.27	0.000**
	Pathan	27	2.93 \pm 0.18	
	Punjabi	27	2.59 \pm 0.22	
	Urdu speaking	27	2.62 \pm 0.39	

RTWIDTH FEMALE: Right width female

p value significant $\leq 0.05^*$, highly significant: $\leq 0.001^{**}$

Test applied: One-Way ANOVA

Table 13

Ethnicity wise comparison of mean width of left frontal sinus among the female groups

N= 108

Parameter	Ethnicity	n	Mean \pm SD	p value
LT WIDTH FEMALE (cm)	Sindhi	27	2.29 \pm 0.23	0.000**
	Pathan	27	3.76 \pm 0.24	
	Punjabi	27	3.42 \pm 0.25	
	Urdu speaking	27	3.37 \pm 0.32	

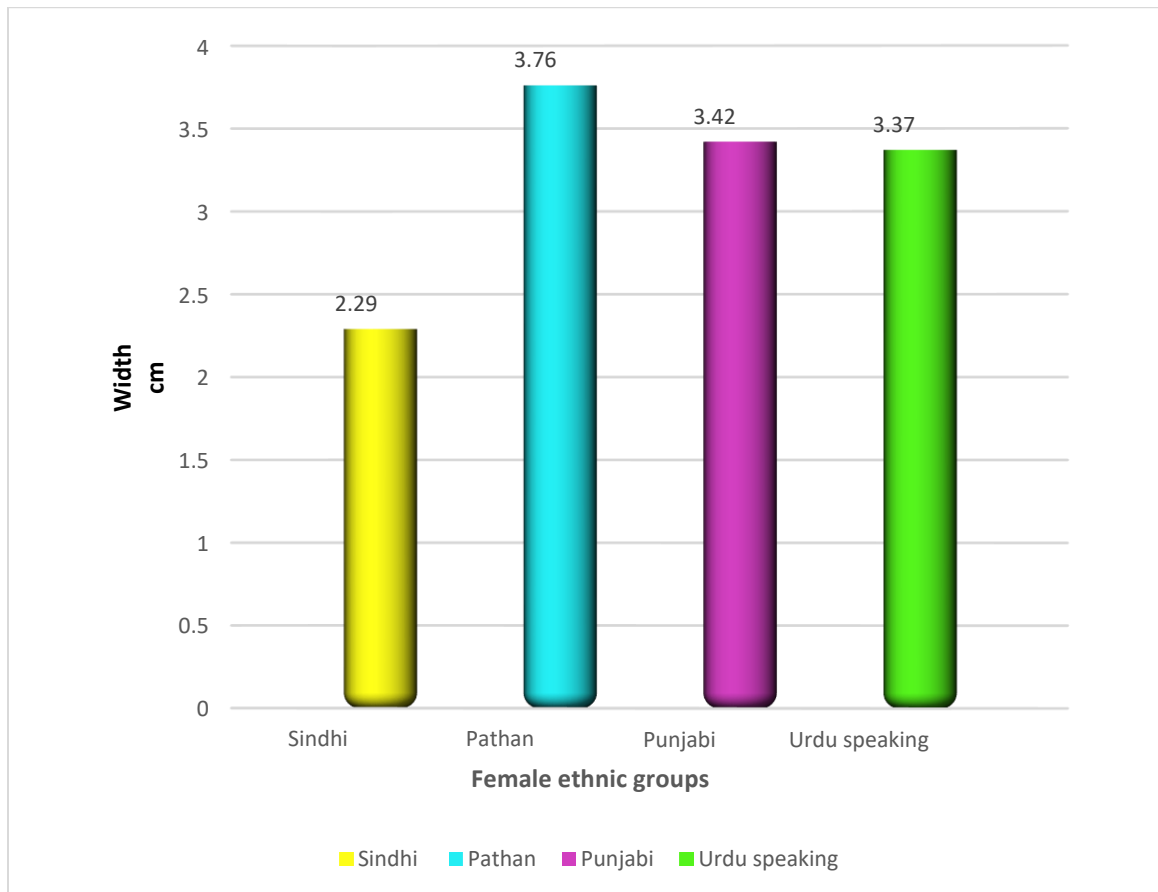
LTWIDTH FEMALE: Left width female

p value significant $\leq 0.05^*$, highly significant: $\leq 0.001^{**}$

Test applied: One-Way ANOVA

Figure 19

Ethnicity wise comparison of mean width of left frontal sinus among the female groups



LT WIDTH: Left width

cm: centimeter

Table 14

Ethnicity wise comparison of mean area of right frontal sinus among the female groups

N= 108

Parameter	Ethnicity	N	Mean \pm SD	p value
RT AREA FEMALE (cm²)	Sindhi	27	1.58 \pm 0.42	0.000**
	Pathan	27	7.39 \pm 1.12	
	Punjabi	27	5.65 \pm 0.60	
	Urdu speaking	27	5.58 \pm 1.07	

RT AREAFEMALE: Right area female

p value significant \leq 0.05*, highly significant: \leq 0.001**

Test applied: One-Way ANOVA

Table 15

Ethnicity wise comparison of mean area of left frontal sinus among the female groups

N= 108

Parameter	Ethnicity	n	Mean \pm SD	p value
LT AREA FEMALE (cm ²)	Sindhi	27	3.18 \pm 0.58	0.000**
	Pathan	27	10.72 \pm 1.40	
	Punjabi	27	8.63 \pm 1.02	
	Urdu speaking	27	8.25 \pm 1.47	

LT AREA FEMALE: Left area female

p value significant $\leq 0.05^*$, highly significant: $\leq 0.001^{**}$

Test applied: One-Way ANOVA

DISCUSSION

The dimensions of the frontal air sinuses in the present study were greater in males as compared to females. In this study, the height of the right frontal air sinus was greater in the males as compared to the females. Similar results were shown by researches conducted on Sudanese and Indian population (Abdurrahman, 2016; Beladavar et al., 2014).

In the current study, left frontal air sinus has shown a greater height in males in comparison to the females. This finding is in agreement with the studies, conducted on the male and female Egyptian adults (Hamed, El-Badrawy, & Fattah, 2014; Eboh et al., 2017; Sherif, Sheta, Ibrahim, Kaka & Henaidy, 2017).

These variations in height observed in the present study can be attributed to the differences in the general structural anatomy and the growth between the two genders (Standring, 2015).

The current study has shown a greater mean width of right and left frontal sinuses in males as compared to females. The results are in agreement with the ones documented in studies conducted on South Indian and Turkish adults (Buyuk et al., 2018 Verma et al., 2014).

Craniofacial architecture contributes in determining the size of the frontal sinuses. The facial architecture is larger in the males than the females (Tehranchi et al., 2017). This could be the explanation of wider widths of frontal air sinuses in the males in contrast to the size of widths in the females.

In the present study, the mean area of the frontal sinuses was significantly larger on the right side in males as compared to the females. Analogous size alterations were noted in terms of the area of left frontal air sinuses in the males in contrast to the females. Similar findings were also reported by the researches conducted on Indian population (Beladavar et al., 2014; Soman et al., 2016). A study done on Indian population has reported non significant variability between genders (Kaur et al., 2013). These smaller areas in females may be due to the overall anatomical variability between the two genders.

The present study demonstrated variance in the dimensions of the frontal sinuses among the different ethnic groups living in Karachi. The mean value for the right frontal air sinus height showed variations in the different male ethnic groups. Dissimilarities were also observed when the left frontal air sinuses dimensions were compared among the four male ethnic groups. The height of the right and the left frontal air sinuses were lowest in the Sindhi males and highest in the Pathan males. The right and the left sided heights of the Punjabi males were higher than that of the Urdu speaking males. Similar variations have also been reported in Indian ethnic groups (Nethan, 2018; Pradhan, 2017). The explanation for the variability in the heights both on the right and the left sides can be attributed to the developmental changes which occur after the frontal sinuses assume their final shape. When the diploe is absorbed in between the two parts of the frontal bone. The resorption of the bone differs in every person (Nikolova et al., 2018).

In the present study, the mean widths of right and the left frontal sinuses have shown significant variation among the male ethnic groups. The Pathan males have the highest measurements followed by the Punjabi, Urdu speaking and the Sindhi males. Differences in the width of left frontal air sinus have also been reported by researches conducted across different regions of India (Chalkoo, Sharma, Nazir & Tariq, 2018; Verma et al., 2014).

This variation in the widths could be due to the process of pneumatization. The two frontal air sinuses acquire pneumatization at a variable pattern and it is independent (Yazici, 2019).

In the current research, the mean value for the right frontal air sinus area in the different male ethnic groups showed significant variations. Dissimilarities were also observed when the left frontal air sinuses area were compared among the four ethnic groups. The mean area of the right and the left frontal air sinuses were lowest in the Sindhi males and highest in the Pathan males among the four male ethnic groups when compared. The right and the left sided area of the Punjabi males were higher than that of the Urdu speaking males. The alterations in the area occupied by the two frontal air sinuses can be explained on the basis of the metopic suture growth pattern variations. The size of the metopic suture in human populations differ and the difference is based on the change in size and growth pattern of the frontal air sinus (Nikolova et al., 2018). The metopic sutures persistence is associated with the smaller sizes of the frontal air sinuses (Guerram, LeMinor, Renger, & Bierry, 2014). Another explanation put forward by Kumar et al.,(2016) is the presence or absence of the inter frontal sinus suture. Inter frontal suture does not exist after the eight years of life but if it does it affects the size pattern of the frontal sinuses.

The current research demonstrated variable mean height of right frontal sinuses among the different ethnic female groups. Similar differences were also noted on the left sides. The dimensions in the Sindhi females were smallest. The Punjabi females showed with the higher dimension higher than the Urdu speaking and the Pathan females showed the highest right and the left frontal sinus heights. Similar ethnic variations have also been reported in Indian population (Sheikh et al., 2018; Soman et al., 2016).

Environmental variations do influence the growth patterns of frontal air sinuses. When the environment changes the size pattern also changes (Kjær et al., 2012).

In the present research, the mean right and the left frontal sinus widths vary among the different female ethnic sub groups. The Pathan females have greatest width for the right frontal air sinuses followed by the Urdu speaking, Punjabi and the Sindhi females. The left sided width was lowest for the Sindhi and highest for the Pathan females. Mean left width for Urdu speaking females was higher than the Punjabi females. Variations in the measurements have also been reported in females of various ethnicities living in India and the Turkish population (Chalkoo et al., 2018; Nethan, 2018). The variation in the right and left frontal sinuses widths among the different female ethnic groups could be due to environmental as well as genetic factors. Both the factors affect the developmental morphology of the two sinuses (Chaiyasate et al., 2007).

In the current research, the mean value for the right frontal air sinus area in the female ethnic groups showed variations. Dissimilarities were also observed when the left frontal air sinuses area were compared among the four female ethnic groups. The mean area of the right and the left frontal air sinuses were lowest in the Sindhi females and highest in the Pathan females. The right and the left sided area of the Punjabi females were higher than that of the Urdu speaking females. Similar variations have also been documented among the female population from different regions of India (Beladavar et al., 2014; Chaudhary & Singh, 2016).

Dimensions of right and left frontal sinuses have also been correlated inversely with handedness. Right handed individuals have greater dimension of the left frontal sinus as compared to the right and vice versa (Kanat, Yazar, Ozdemir, Coskun, & Erdivanli, 2017).

CONCLUSION

The study has enabled to come up with the following conclusions regarding the anatomy of frontal air sinuses

The height, width and area were bigger in males as compared to the females on both left and the right sides.

The height, width and the area of the right and the left frontal air sinuses have shown significant variability among the male members of studied ethnic groups.

Significant differences in the height, width and area were also noted among the female members of studied ethnic groups.

The outcomes and results of this research provide discernment of the anatomical variability of frontal air sinuses and can contribute in terms of new knowledge to the disciplines of anthropology and the forensic science.

6.1 Recommendations

1. We need to develop a system that saves the Water's view radiographic records of the individuals (similar to the finger printing data record). The records can certainly benefit both the forensic experts as well as the anthropologists in identifying the severely charred unknown bodies by comparison of the antemortem radiographs with that of the postmortem radiographs.
2. The cost effective and simple method of radiography can prevent the agencies from employment of techniques that require extensive finance as well as incorporation of lengthy procedures like DNA analysis.

3. There is a need to extend this study in multiple centers of Karachi in order to include all the other ethnicities and to document the variations on a whole.

6.2 Strengths of study

1. The main strength of the study is its objective. Utilizing anatomical features as source and tool in identification has never been used before in Pakistan. This study is the first of its type in our country.
2. This can be very cost effective and helpful for the fields of forensic science and anthropology.

6.3 Limitations of study

Nevertheless, the limitations of the study are mentioned as under

1. The sampling technique that was used, was convenience sampling. This type of sampling is associated with bias in the result.
2. The study was conducted at a single center, therefore results cannot be generalized.

7.1 REFERENCES

- Abdurrahman, M. M. (2016). *Determination of Normal Frontal Sinuses Dimensions Using Computed Tomography* (PhD thesis). Retrieved from [http://: repository.sustech.edu](http://repository.sustech.edu)
- Ahmed, S. A., Salem, H. E., & Fawzy, M. M. (2018). Forensic dissection of lip print as an investigative tool in a mixed Egyptian population. *Alexandria Journal of Medicine*, 54(3), 235-239.
- Alrumaih, R.A., Ashoor, M.M., Obidan, A. A., Al-Khater, K.M., & Al-Jubran, S.A. (2016). Radiological sinonasal anatomy: exploring the Saudi population. *Saudi Medical Journal*, 37(5),521-526.
- Alshaikh, N., & Aldhurai, A. (2018). Anatomic variations of the nose and paranasal sinuses in Saudi population: computed tomography scan analysis. *The Egyptian Journal of Otolaryngology*, 34(4), 234-241.
- Amusa, Y. B., Eziyi, J. A., Akinlade, O., Famurewa, O. C., Adewole, S. A., Nwoha, P. U., & Ameye, S. A. (2011). Volumetric measurements and anatomical variants of paranasal sinuses of Africans (Nigerians) using dry crania. *International Journal of Medical Sciences*, 3(10), 299-303.
- Ashwinirani, S. R., Suragimath, G., Sande, A. R., Kulkarni, P., Nimbale, A., Shankar, T., ... & Shetty, P.K. (2014). Comparison of lip print patterns in two Indian sub populations and its correlation in ABO blood groups. *Journal of Clinical and Diagnostic Research*, 8(10),40-43.
- Aslier, N. G. Y., Karabay, N., Zeybek, G., Keskinoglu, P., Kiray, A., Sutay, S., & Ecevit, M. C. (2016). The classification of frontal sinus pneumatization patterns by CT-based volumetry. *Surgical and Radiologic Anatomy*, 38(8), 923-930.
- Aydinlioglu, A., Kavakli, A., & Erdem, S. (2003). Absence of frontal sinus in Turkish individuals. *Yonsei Medical Journal*, 44(2), 215-218.

- Beaini, T. L., Duailibi-Neto, E. F., Chilvarquer, I., & Melani, R. F. (2015). Human identification through frontal sinus 3D superimposition: Pilot study with Cone Beam Computer Tomography. *Journal of Forensic and Legal Medicine*, 36, 63-69.
- Belaldavar, C., Kotrashetti, V. S., Hallikerimath, S. R., & Kale, A. D. (2014). Assessment of frontal sinus dimensions to determine sexual dimorphism among Indian adults. *Journal of Forensic Dental Sciences*, 6(1),25-30.
- Benghiac, A. G., Moscalu, M., & Denisia, H.A.B.A. (2017). Gender determination by linear measurements of the frontal sinus using CBCT scans. *The Medical-Surgical Journal*, 121(3),470-478.
- Bilgin, S., Kantarcı, U. H., Duymus, M., Yildirim, C. H., Ercakmak, B., Orman, G., ...& Akbasak, A. (2013). Association between frontal sinus development and persistent metopic suture. *Folia Morphologica*, 72(4), 306-310.
- Burns, K. R. (2015). *Forensic anthropology training manual*. New York: Routledge publishing press.
- Buyuk, S. K., Simsek, H., & Karaman, A. (2018).The relationship between frontal sinus morphology and skeletal maturation.*Folia Morphologica*, 77(3), 503-508.
- Byers, S. N. (2016).*Introduction to forensic anthropology* (5th ed.). Manoa,USA: Taylor & Francis.
- Çakur, B., Sumbullu, M. A., & Durna, N. B. (2011). Aplasia and agenesis of the frontal sinus in Turkish individuals: a retrospective study using dental volumetric tomography. *International Journal of Medical Sciences*, 8(3), 278-283.
- Calafell, F., & Larmuseau, M. H. (2017). The Y chromosome as the most popular marker in genetic genealogy benefits interdisciplinary research. *Human genetics*, 136(5), 559-573.
- Camargo, J. R., Daruge, E., Prado, F. B., Caria, P. H., Alves, M. C., Silva, R. F.,et al. (2007). The frontal sinus morphology in radiographs of Brazilian subjects; its forensic importance.*Brazilian Journal of Morphological Science*, 24, 239-43.

- Cappello, Z. J., & Dublin, A. B. (2018). *Anatomy, Head, Sinuses, Paranasal*. Treasure Island, FL: Stat Pearls Publishing Press.
- Carles, M., Levraut, J., Gonzalez, J. F., Valli, F., & Bornard, L. (2016). Mass casualty events and health organisation: terrorist attack in Nice. *The Lancet*, 388(10058), 2349-2350.
- Cattaneo, C. (2017). Overview Forensic Anthropology: An Introduction. *Forensic Anthropology*, 2352(6238), 1-6.
- Čechová, M., Dupej, J., Brůžek, J., Bejdová, Š., Horák, M., & Velemínská, J. (2019). Sex estimation using external morphology of the frontal bone and frontal sinuses in a contemporary Czech population. *International Journal of Legal Medicine*, 42(3), 1-10.
- Chaiyasate, S., Baron, I., & Clement, P. (2007). Analysis of paranasal sinus development and anatomical variations: a CT genetic study in twins. *Clinical Otolaryngology*, 32(2), 93-97.
- Chalkoo, A. S., Sharm, P., Nazir, N., & Tariq, S. (2018). Evaluation of the frontal sinuses dimensions in sex estimation among a sample of adult Kashmiri population using multidetector computed tomography. *International Journal of Maxillofacial Imaging*, 4(4), 122-125.
- Chaudhary, S., & Singh, U. (2016). Uniqueness of frontal sinus as tool for personal identification in forensic odontology. *Annals of International Medical and Dental Research*, 2, 7-9.
- Choi, I. G., Duailibi-Neto, E. F., Beaini, T. L., da Silva, R. L., & Chilvarquer, I. (2018). The Frontal Sinus Cavity Exhibits Sexual Dimorphism in 3D Cone-beam CT Images and can be Used for Sex Determination. *Journal of Forensic Sciences*, 63(3), 692-698.
- Choudhary, A., Lemos, R., & Van Reenen, J. (2018). Management in Pakistan: Performance and conflict. *International Growth Center*, 89451, 1-46.
- Christensen, A. M., & Hatch, G. M. (2018). *New Perspectives in Forensic Human Skeletal Identification*. USA: Academic Press.

- Ciaffi, R., Gibelli, D., & Cattaneo, C. (2011). Forensic radiology and personal identification of unidentified bodies: a review. *La Radiologia Medica*, 116(6), 960-968.
- Cohen, O., Warman, M., Fried, M., Shoffel-Havakuk, H., Adi, M., Halperin, D., & Lahav, Y. (2018). Volumetric analysis of the maxillary, sphenoid and frontal sinuses: a comparative computerized tomography based study. *Auris Nasus Larynx*, 45(1), 96-102.
- Cossellu, G., De Luca, S., Biagi, R., Farronato, G., Cingolani, M., Ferrante, L., & Cameriere, R. (2015). Reliability of frontal sinus by cone beam-computed tomography (CBCT) for individual identification. *La Radiologia Medica*, 120(12), 1130-1136.
- Cox, M., Malcolm, M., & Fairgrieve, S. I. (2009). A new digital method for the objective comparison of frontal sinuses for identification. *Journal of Forensic Sciences*, 54(4), 761-772.
- Crawford, M.H., & Beaty, K.G. (2013). DNA finger printing in anthropological genetics: past, present, future. *Investigative Genetics*, 4(1), 23.
- Crosta, E. (2016). *Sexual Determination from Frontal Sinus Analysis in a Subadult Population Using Archival Radiographic Records* (PhD thesis). Retrieved from <http://digitalscholarship.unlv.edu/thesisdissertations/2858/>
- Culbert, W. L., & Law, F. M. (1927). Identification by comparison of roentgenograms of nasal accessory sinuses and mastoid processes. *Journal of the American Medical Association*, 88(21), 1634-1636.
- Culver, A., RoCHAT, R., & Cookson, S. T. (2017). Public health implications of complex emergencies and natural disasters. *Conflict and health*, 11(1), 32.
- Da Silva, I. D. N., Fernandes, K. J. D. M., Ramalho, A. J. C., Bispo, R. F. M., Rodrigues, C. F. D. S., & Aragão, J. A. (2013). Occurrence of metopism in dry crania of adult Brazilians. *International Scholarly Research Notices*. 158341, 1-4.

- Da Silva, R. F., Rodrigues, L. G., Picoli, F. F., Bueno, J. M., Franco, R. P. A. V., & Franco, (2019). Morphological analysis of frontal sinuses registered in an occlusal film by intraoral radiographic device—a case report. *Journal of Forensic Radiology and Imaging*, 5(3),414-419.
- Dafalla, S. E., Seyed, M. A., Elfadil, N. A., Elmustafa, O. M., & Hussain, Z. (2017).A Computed Tomography-Aided Clinical Report on Anatomical Variations of the Paranasal Sinuses.*Global Journal of Medical Research*. 6(2), 24-33.
- DeBoer, H.H., Maat, G.J., Kadarmo, D.A., Widodo, P.T., Kloosterman, A.D., & Kal, A.J. (2018).DNA identification of human remains in Disaster Victim Identification (DVI): An efficient sampling method for muscle, bone, bone marrow and teeth. *Forensic Science International*, 289, 253-259.
- Demiralp, K., Cakmak, S. K., Aksoy, S., Bayrak, S., Orhan, K., & Demir, P. (2018). Assessment of paranasal sinus parameters according to ancient skulls' gender and age by using cone beam computed tomography. *Folia Morphologica*, 5603, 89-92.
- Dhall, J. K., & Kapoor, A. K. (2016). Fingerprint ridge density as a potential forensic anthropological tool for sex identification. *Journal of Forensic Sciences*, 61(2), 424-429.
- Dhiman, I., Singla, A., Mahajan, V., Jaj, H. S., Seth, V., & Negi, P. (2015). Reliability of frontal sinus with that of maxillary sinus in assessment of different types of skeletal malocclusions. *Journal of Indian Orthodontic Society*, 49(2), 96.
- Drake,R.,Vogl,A.W., & Mitchell,A.W. (2019). *Gray's Anatomy for Students* (2nded.). Ohio, USA: Elsevier Publisher.
- Duque, C. S., & Casiano, R. R. (2005). *The frontal sinus*. Berlin: Heidelberg: Springer
- Eboh, D. E. O., Ogbeide, O. U., & Ivwighren, T. (2017). Radiographic anthropometric study of frontal sinus for sex determination in Benin city, South-South Nigeria. *Journal of Forensic Dental Sciences*, 9(1), 31.

- Edson, S. M., Root, K. A., Kahline, I. L., Dunn, C. A., Trotter, B. E., & O' Rourke, J. A. (2018). *New Perspectives in Forensic Human Skeletal Identification*. CA, USA: Academic Press Publisher.
- Erturk, S. M., Ondategui-Parra, S., Otero, H., & Ros, P. R. (2006). Evidence-based radiology. *Journal of the American College of Radiology*, 3(7), 513-519.
- Ezemagu, U. K., Anibeze, C. I., & Akpuaka, F. C. (2017). Sexual dimorphism in frontalsinus of Southeast Nigerians. *Annals of Bioanthropology*, 5(1),14.
- Fernandes, C. L. (2018). *The paranasal air sinuses in the human: An Anatomical Assessment using Computed Tomography. Applications to Human Forensic Identification* (PhD thesis). Retrieved from <http://qmro.qmul.ac.uk/xmlui/handle/31729>
- Ferreira Silva, R., Fortes Picoli, F., de Lucena Botelho, T., Gomes Resende, R., & Franco, (2017). Forensic Identification of Decomposed Human Body through Comparison between Ante-Mortem and Post-Mortem CT Images of Frontal Sinuses: Case Report. *Acta Stomatologica Croatica*, 51(3),227-231.
- Ferreira-Silva, R., Meirelles, A. P. D. A., Machado, I., Grazielle, L., Rodrigues, R. G. R., Picapedra, A., & Sassi, C. (2018). Skeletonized body identified by analysis of frontal sinus morphology and characteristics of osteosynthesis material: a forensic case report. *Odontoestomatologia*, 20(31),45-49.
- Gadekar, N. B., Kotrashetti, V. S., Hosmani, J., & Nayak, R. (2019).Forensic application of frontal sinus measurement among the Indian population. *Journal of Oral and Maxillofacial Pathology*, 23(1), 147.
- Galán,A.,Carlos,J.,& Reyes Téllez Girón, J. (2016).Anatomic evaluation and description of the frontal sinus in the Mexican population between 20 to 60 years old through computed tomography. *Archivos De Neurociencias*, 21(1),23-31.

Gibelli, D., Cellina, M., Cappella, A., Gibelli, S., Panzeri, M. M., Oliva, A. G., ... & Sforza, C. (2018). An innovative 3D-3D superimposition for assessing anatomical uniqueness of frontal sinuses through segmentation on CT scans. *International Journal of Legal Medicine*, 36, 1-7.

González-Colmenares, G., Medina, C. S., Rojas-Sánchez, M. P., León, K., & Malpud, A. (2019). Sex estimation from skull base radiographs in a contemporary Colombian population. *Journal of Forensic and Legal Medicine*, 62, 77-81.

Goodwin, W. H., & Simmons, T. (2017). Disaster Victim Identification. *Forensic Science Medical Pathology*, 2(3), 203-207.

Gopal, K. S., & Vijayan, B. P. (2016). Significance of frontal sinus and nasal septum patterns in personal identification in forensics: A retrospective CBCT study. *International Journal of Oral Health Medical Research*, 2, 57-62.

Gotlib, T., Kuźmińska, M., Held-Ziółkowska, M., Osuch-Wójcikiewicz, E., & Niemczyk, . (2015). Hidden unilateral aplasia of the frontal sinus: a radioanatomic study. *International Forum of Allergy & Rhinology*, 5, 441-444.

Gowland, R., & Thompson, T. (2013). *Human Identity and Identification*. Cambridge: Cambridge University Press.

Goyal, M., Acharya, A. B., Sattur, A. P., & Naikmasur, V. G. (2013). Are frontal sinuses useful indicators of sex? *Journal of Forensic and Legal Medicine*, 20(2), 91-94.

Guerram, A., LeMinor, J. M., Renger, S., & Bierry, G. (2014). Brief communication: The size of the human frontal sinuses in adults presenting complete persistence of the metopic suture. *American Journal of Physical Anthropology*, 154(4), 621-627.

Hacl, A., Costa, A. L. F., Oliveira, J. M., Tucunduva, M. J., Girondi, J. R., & Nahás-Scocate, A. C. R. (2017). Three-dimensional volumetric analysis of frontal sinus using medical software. *Journal of Forensic Radiology and Imaging*, 11, 1-5.

- Hamed, S. S., El-Badrawy, A. M., & Fattah, S. A. (2014). Gender identification from frontal sinus using multi-detector computed tomography. *Journal of Forensic Radiology and Imaging*, 2(3), 117-120.
- Handa, R., Sheikh, S., Shambulingappa, P., Aggarwal, A., Singh, R., Gupta, D., ...&Salaria S.(2015).BilateralAbsenceofFrontalSinusandUnilateralMandibularHypoplasia.A Case report.*Bangladesh Journal of Dental Research & Education*, 5(1), 29-32.
- Hanson, C. L., & Owsley, D. W. (1980). Frontal sinus size in Eskimo populations.*American Journal of Physical Anthropology*, 53(2), 251-255.
- Henson,B., & Edens, M.A. (2018). *Anatomy, Head and Neck, Nose Sinuses*. Treasure Island, FL: Stat Pearls Publishing.
- Hiatt, J. L., & Gartner, L. P. (2009).*Textbook of head and neck anatomy*. New York, USA: Lippincott Willaims Wilkins.
- House, L. K., Stringer, S. P., & Seals, S. (2017). Correlation of frontal sinus recess anatomy with ethnicity, gender, and pathology. *American Journal of Otolaryngology*, 38(4), 452-455.
- Iino, M., Fujimoto, H., Yoshida, M., Matsumoto, H., & Fujita, M. Q. (2016). Identification of a jawless skull by superimposing post-mortem and ante-mortem CT. *Journal of Forensic Radiology and Imaging*, 6, 31-37.
- Kahali, R., & Tootoonchian, A. (2015). *Textbook of Advanced Oral and Maxillofacial Surgery*.Rijeka, Croatia: Intech Press.
- Kanat, A., Yazar, U., Ozdemir, B., Coskun, Z. O., & Erdivanli, O. (2015). Frontal sinus asymmetry: Is it an effect of cranial asymmetry? X-ray analysis of 469 normal adult human frontal sinus. *Journal of neurosciences in rural practice*, 6(4), 511.
- Kanjani, V., Rani, A., & Kanjani, D. (2019). Morphometric analysis of the orbital aperture in North Indian Population: A retrospective digital forensic study. *International Journal of Applied and Basic Medical Research*, 9(2), 85.

- Katz, E., & Halámek, J. (2016). *Forensic science: A multidisciplinary approach*. NY, USA: Wiley Publisher.
- Kaur, N., Sunira, C., Parvathi, D., Raju, M., Neeraj, T., & Ruhi, S. (2013). The forensic importance of frontal sinus in gender discrimination: amorphometric study. *Journal of Oral Sign*, 5(1),2-5.
- Kim, D. I., Lee, U. Y., Park, S. O., Kwak, D. S., & Han, S. H. (2013). Identification using frontal sinus by three -dimensional reconstruction from computed tomography. *Journal of Forensic Sciences*, 58(1),5-12.
- Kjær,I.,Pallisgaard,C.,& Brock-Jacobsen, M.T. (2012). Frontal sinus dimensions can differ significantly between individuals within a monozygotic twin pair, indicating environmental influence on sinus sizes. *Acta oto-laryngologica*, 132(9),988-994.
- Koertvelyessy T. (1972). Relationships between the frontal sinus and climatic conditions: A skeletal approach to cold adaptation. *American Journal of Physical Anthropology*, 37,161-172.
- Konigsberg, L. W., & Jantz, L. M. (2017). The probabilistic basis for identifying individuals in biohistorical research. *Studies in Forensic Biohistory. Anthropological Perspectives*, 75, 213-217.
- Korkmaz, H., & Korkmaz, M. (2013). Total aplasia of the paranasal sinuses. *Allergy & Rhinology*, 4(2), 102-109.
- Kumar,N.V.,Vijayashanmugam,U.,Gugapriya,T.S.,Nalinakumari,S.D.,&Kumar,N.V. (2016). A roentgen-anatomic study of association between persistent inter-frontal suture with varied presence of frontal sinus. *Indian Journal of Clinical Anatomy and Physiology*, 3(4), 510-513.
- Kumar,P.,Rakesh,B.S.,&Prasad,R.(2016).AnatomicalVariationsofSinonasalRegion,A Coronal CT Scan Study. *International Journal of Contemporary Medical Research*, 3(9),2601-2604.

- Kumar, R., Athota, A., Rastogi, T., & Karumuri, S. K. (2015). Forensic radiology: An emerging tool in identification. *Journal of Indian Academy of Oral Medicine and Radiology*, 27(3), 416.
- Latham, K. E., Bartelink, E. J., & Finnegan, M. (2017). *New perspectives in forensic human skeletal identification*. Academic Press.
- Lei, G., Liu, F., Liu, P., Zhou, Y., Jiao, T., & Dang, Y. H. (2019). Worldwide tendency and focused research in forensic anthropology: A bibliometric analysis of decade (2008–2017). *Legal Medicine*, 37, 67-75.
- Luo, H., Wang, J., Zhang, S., & Mi, C. (2018). The application of frontal sinus index and frontal sinus area in sex estimation based on lateral cephalograms among Han nationality adults in Xinjiang. *Journal of Forensic and Legal Medicine*, 56, 1-4.
- Lynn, M., & Lieberman, H. (2019). *Disasters and Mass Casualty Incidents: The Nuts and Bolts of Preparedness and Response to Protracted and Sudden Onset Emergencies*. Springer.
- Manigandan, T., Sumathy, C., Elumalai, M., Sathasivasubramanian, S., & Kannan, A. (2015). Forensic radiology in dentistry. *Journal of Pharmacy & Bioallied Sciences*, 7(1), 260- 265.
- Márquez, S., Lawson, W., Mowbray, K., Delman, B. N., & Laitman, J. T. (2015). CT Examination of Nose and Paranasal Sinuses of Egyptian Mummies and Three Distinct Human Population Groups: Anthropological and Clinical Implications. *The Anatomical Record*, 298(6), 1072-1084.
- Marsya, G., Sasmita, I. S., & Oscandar, F. (2017). Overview of the frontal sinus anteroposterior size based on against lateral cephalometric radiographs chronological age as forensic identification. *Padjadjaran Journal of Dentistry*, 29(2), 113-117.
- Mathur, H., Mathur, A., Ahmed, J., Khorate, M., & Tripathi, P. (2013). Conventional frontal sinus imaging in identification of sex: original study in population of Udaipur City. India. *Journal of Medical Science and Clinical Research*, 1(1), 33-37.

- Milligan, C. F., Finlayson, J. E., Cheverko, C. M., & Zarenko, K. M. (2018). *Advances in the Use of Craniofacial Superimposition for Human Identification. In New Perspectives in Forensic Human Skeletal Identification*. Academic Press.
- Mohan, G., & Dharman, S. (2019). Sex Determination and Personal Identification using Frontal Sinus and Nasal Septum—A Forensic Radiographic Study. *International Journal of Operational Research*, 13(1), 125-130.
- Moore, K., & Ross, A. (2017). Frontal sinus development and juvenile age estimation. *The Anatomical Record*, 300(9), 1609-1617.
- Moretti, T. R., Moreno, L. I., Smerick, J. B., Pignone, M. L., Hizon, R., Buckleton, J. S., ... & Onorato, A. J. (2016). Population data on the expanded CODIS core STR loci for eleven populations of significance for forensic DNA analyses in the United States. *Forensic Science International Genetics*, 25, 175-181.
- Motawei, S. M., Wahba, B. A., Aboelmaaty, W. M., & Tolba, E. M. (2016). Assessment of frontal sinus dimensions using CBCT to determine sexual dimorphism amongst Egyptian population. *Journal of Forensic Radiology and Imaging*, 6, 8-13.
- Nagaraj, T., Nigam, H., Santosh, H. N., Sumana, C. K., Gogula, S., & Sahu, P. (2017). Personal identification using frontal sinus and nasal septum patterns in forensic medicine: A retrospective digital radiographic study. *Journal of Medicine, Radiology, Pathology and Surgery*, 4(5), 5-8.
- Najam, N. U. S., & Mehmood, A. M. (2019). The economic cost of terrorism and natural disasters: A deeper analysis of the financial markets of Pakistan. Retrieved from <https://mpa.ub.uni-muenchen.de/92278/>
- Nateghian, Z., Abedi, I., Dashti, G. H., Faraji B. (2016). Frontal Sinus Pattern and Evaluation of Right and Left Frontal Sinus Volume According to Gender, Using Multi Detector CT Scan. *Journal of Forensic Science & Criminology*, 4(4), 1-4.

- Nathani, R., Diagavane, P., Shrivastav, S., Kamble, R., Gupta, D., & Korde, S. (2016). Evaluation of frontal sinus as a growth predictor in horizontal, vertical, and average growth pattern in children from 8 to 11 years: A cephalometric study. *Journal of Indian Orthodontic Society*, 50(2), 101.
- Nethan, S. T. (2018). Frontal Sinus Dimensions: An Aid in Gender Determination. *Acta Scientific Dental Sciences*, 2, 2-6.
- Netter, F. H. (2017). *Atlas of Human Anatomy Book*. Elsevier Health Press.
- Nikam, S. S., Gadgil, R. M., Bhoosreddy, A. R., Shah, K. R., & Shirsekar, V. U. (2015). Personal identification in forensic science using uniqueness of radiographic image of frontal sinus. *The Journal of Forensic Odonto-stomatology*, 33(1), 1.
- Nikolova, S., Toneva, D., Georgiev, I., & Lazarov, N. (2018). Digital radiomorphometric analysis of the frontal sinus and assessment of the relation between persistent metopic suture and frontal sinus development. *American Journal of Physical Anthropology*, 165(3), 492-506.
- Oktem, H., Kurkcuglu, A., Pelin, I. C., Yazici, A. C., Aktaş, G., & Altunay, F. (2015). Sex differences in fingerprint ridge density in a Turkish young adult population: A sample of Baskent University. *Journal of Forensic and Legal Medicine*, 32, 34-38.
- Pandeshwar, P., Kumar, N. N., Shastry, S. P., Ananthaswamy, A., & Markande, A. (2017). Sexual dimorphism of radiomorphological features of frontal sinus. *International Journal of Forensic Odontology*, 2(2), 46.
- Patil, K., & Mody, R. N. (2005). Determination of the sex by discriminant function analysis and stature by regression analysis: A lateral cephalometric study. *Forensic Science International*, 147, 125-80.
- Patil, N., Karjodkar, F. R., Sontakke, S., Sansare, K., & Salvi, R. (2012). Uniqueness of radiographic patterns of the frontal sinus for personal identification. *Imaging science in dentistry*, 42(4), 213-217.

- Pradhan, A. (2017). Measurement of different dimension of maxillary and frontal sinus through computed tomography. *Journal of Health and Allied Sciences*, 16(1),1-3.
- Prado, F. B., Freire, A. R., Rondon, B. C. S., Costa, S. T., Rossi, A. C., & Daruge Júnior, E. (2016).Analysis of the frontal sinus morphology and the titanium plates shape in skull fracture for human identification. *International Journal of Odontostomatology*, 10(2), 303-8.
- Rabelo, K. A., dos Anjos Pontual, M. L., de Queiroz Jordão, N., de Paiva, K. M., de Moraes Ramos-Perez, F. M., dos Santos, M. S., & dos Anjos Pontual, A. (2016). Human identification by FSS system adapted to cephalometric radiographs. *Forensic Science International*, 262, 227-232.
- Raina, A., Ravindra, S. V., Malik, U., & Yeluri, G. (2019). Imaging In Identification. *Journal of Pearlident*, 9(3), 1-5.
- Ramaswamy, P., & Khaitan, T. (2014). Frontal sinus index–A new tool for sex determination. *Journal of Forensic Radiology and Imaging*, 2(2), 77-79.
- Rampant, S., Coumbaros, J., & Chapman, B. (2019). Post-blast detection of human DNA on improvised explosive device fragments. *Australian Journal of Forensic Sciences*,5,1- 4.
- Ribeiro, Q., & De Andrade, F. (2000). Standardized measurements of radiographic films of the frontal sinuses: An aid to ENT. *Ear, Nose & Throat Journal*, 79(1),26-28.
- Richer, S. M. (2015). Getting into shape: a comparison of three methods used to characterize personal uniqueness of the frontal sinuses using computed tomography (CT) data (PhD thesis). Retrieved from <http://mspace.lib.umanitoba.ca.org>.
- Rigby, N., & Kulathinal, R. J. (2015).Genetic architecture of sexual dimorphism in humans. *Journal of Cellular Physiology*, 230(10), 2304-2310.
- Ruf, S., & Pancherz, H. (1996).Development of the frontal sinus in relation to somatic and skeletal maturity.A cephalometric roentgenographic study at puberty. *The European Journal of Orthodontics*, 18(1), 491-497.

- Said, O. T., Rossouw, P. E., Fishman, L. S., & Feng, C. (2017). Relationship between anterior occlusion and frontal sinus size. *The Angle Orthodontist*, 87(5),752-758.
- Schuller, A. (1943). A note on the identification of skulls by X-ray pictures of the frontal sinuses. *Medical Journal of Australia*, 1(25), 554-556.
- Shapiro, R., & Schorr, S.(1980). A consideration of the systemic factors that influence frontal sinus pneumatization. *Investigative radiology*,15(3),191- 202.
- Sheikh, N. N., Ashwinirani, S. R., Suragimath, G., & Kumar, K. S. (2018). Evaluation of gender based on the size of maxillary sinus and frontal sinuses in paranasal sinus view radiographs in Maharashtra population, India. *Journal of Oral Research and Review*, 10(2),57.
- Sherif, N. A. E. H., Sheta, A. A. E. M., Ibrahim, M. E., Kaka, R. A. E. M., & Henaidy, M. F. (2017). Evaluation of the paranasal sinuses dimensions in sex estimation among a sample of adult Egyptians using multidetector computed tomography. *Journal of Forensic Radiology and Imaging*, 11, 33-39.
- Sheriff,R.M.,&Moideen,C.P.(2017).Incidence of frontal sinus aplasia in Indian population. *International Journal of Otorhinolaryngology and Head and Neck Surgery*, 3(1),108.
- Silva, R. F., Franco, A., Saboia, L. R., Rodrigues, L. G., & Gomes, R. R. (2015).Identification of a Charred Body through the Radiographic Morphology of the Frontal Sinus – A Case Report. *Annals of Forensic Residence*, 2(1),10-14.
- Silva, R. F., Mundim, M. B. V., Picoli, F. F., & Franco, A. (2015).Dental identification of a mummified body using dental cast and prosthesis. *Journal Forensic Investigation*,3(2), 3.
- Sinnatamby, C. S. (2011). *Last's Anatomy, Regional and Applied*. Elsevier Health Sciences.
- Snell, R. S. (2011). *Clinical anatomy by regions*.Lippincott Williams & Wilkins.

- Soares, C. B. R. B., Almeida, M. S. C., Lopes, P. D. M. L., Beltrão, R. V., dos Anjos Pontual, A., de Moraes Ramos-Perez, F. M., ... & dos Anjos Pontual, M. L. (2016). Human identification study by means of frontal sinus imaginological aspects. *Forensic Science International*, 262,183-189.
- Soman, B. A., Sujatha, G. P., & Lingappa, A. (2016). Morphometric evaluation of the frontal sinus in relation to age and gender in subjects residing in Davangere, Karnataka. *Journal of Forensic Dental Sciences*, 8(1), 57.
- Stamm, A. C. (2000). Micro-endoscopic surgery of the paranasal sinuses. Berlin, Heidelberg: Springer.
- Standring,S.(2015).*Gray's Anatomy International Edition: The Anatomical Basis of Clinical Practice*. Elsevier Health Sciences.
- Stavrianos, C., Papadopoulos, C., Petalotis, N. (2013). Identification by Frontal Sinus. *Research Journal of Medical Sciences*, 7(1), 5-8.
- Suman, J. L., Jaisanghar, N., Elangovan, S., Mahaboob, N., Senthilkumar, B., Yoithapprabhunath, T.R., & Srichinthu,K.K.(2016). Configuration of frontal sinuses: A forensic perspective. *Journal of Pharmacy & Bioallied Sciences*, 8(1),90-95.
- Szilvássy, J. (1981). Development of the frontal sinuses. *Anthropologischer Anzeiger*, 39,138-49.
- Tarani, S., Kamakshi, S. S., Naik, V., & Sodhi, A. (2017). Forensic radiology: An emerging science. *Journal of Advanced Clinical and Research Insights*, 4(2), 59-63.
- Tatlisumak, E., Asirdizer, M., Bora, A., Hekimoglu, Y., Etlı, Y., Gumus, O., & Keskin, S. (2017). The effects of gender and age on forensic personal identification from frontal sinus in a Turkish population.*Saudi Medical Journal*, 38(1), 41.
- Tehranchi, A., Motamedian, S. R., Saedi, S., Kabiri, S., & Shidfar, S. (2017). Correlation between frontal sinus dimensions and cephalometric indices: A cross-sectional study. *European Journal of Dentistry*, 11(1), 64.

- Tiwari, P., Bhovi, T. V., Jaju, P. P., Gupta, M., & Shrivastava, K. (2016). Frontal Sinus-A Useful Personal Identification Tool. *Journal of Oral Medicine, Oral Surgery, Oral Pathology and Oral Radiology*, 2(1), 11-22.
- Trant, M., & Christensen, A. M. (2018). Frontal Sinus Absence Rates in Various Populations Implications for Forensic identification. *Forensic Anthropology*, 1(2), 99-105.
- Ubelaker, D. H., Shamlou, A., & Kunkle, A. (2019). Contributions of forensic anthropology to positive scientific identification: a critical Review. *Forensic Sciences Research*, 4(1), 45-50.
- Uthman, A. T., Al-Rawi, N. H., Al-Naaimi, A. S., Tawfeeq, A. S., & Suhail, E. H. (2010). Evaluation of frontal sinus and skull measurements using spiral CT scanning: an aid in unknown person identification. *Forensic Science International*, 197, 1-3.
- Vaid, S., & Vaid, N. (2015). Normal anatomy and anatomic variants of the paranasal sinuses on computed tomography. *Neuroimaging Clinics*, 25(4), 527-548.
- Vallis, J. (2017). *The role of radiography in disaster victim identification. In Human Remains: Another Dimension*. Academic Press.
- Verma, K., Nahar, P., Singh, M. P., Mathur, H., & Bhuvaneshwari, S. (2017). Use of Frontal Sinus and Nasal Septum Pattern as an Aid in Personal Identification and Determination of Gender: A Radiographic Study. *Journal of clinical and diagnostic research*, 11(1), 71-74.
- Verma, P., Verma, K. G., Khosa, R., Kumar, S., Basavaraju, S., & Patwardhan, N. (2015). Combined use of frontal sinus and nasal septum patterns as an aid in forensics: A digital radiographic study. *North American Journal of Medical Sciences*, 7(2), 47.
- Verma, S., Mahima, V. G., & Patil, K. (2014). Radiomorphometric analysis of frontal sinus for sex determination. *Journal of Forensic Dental Sciences*, 6(3), 177.

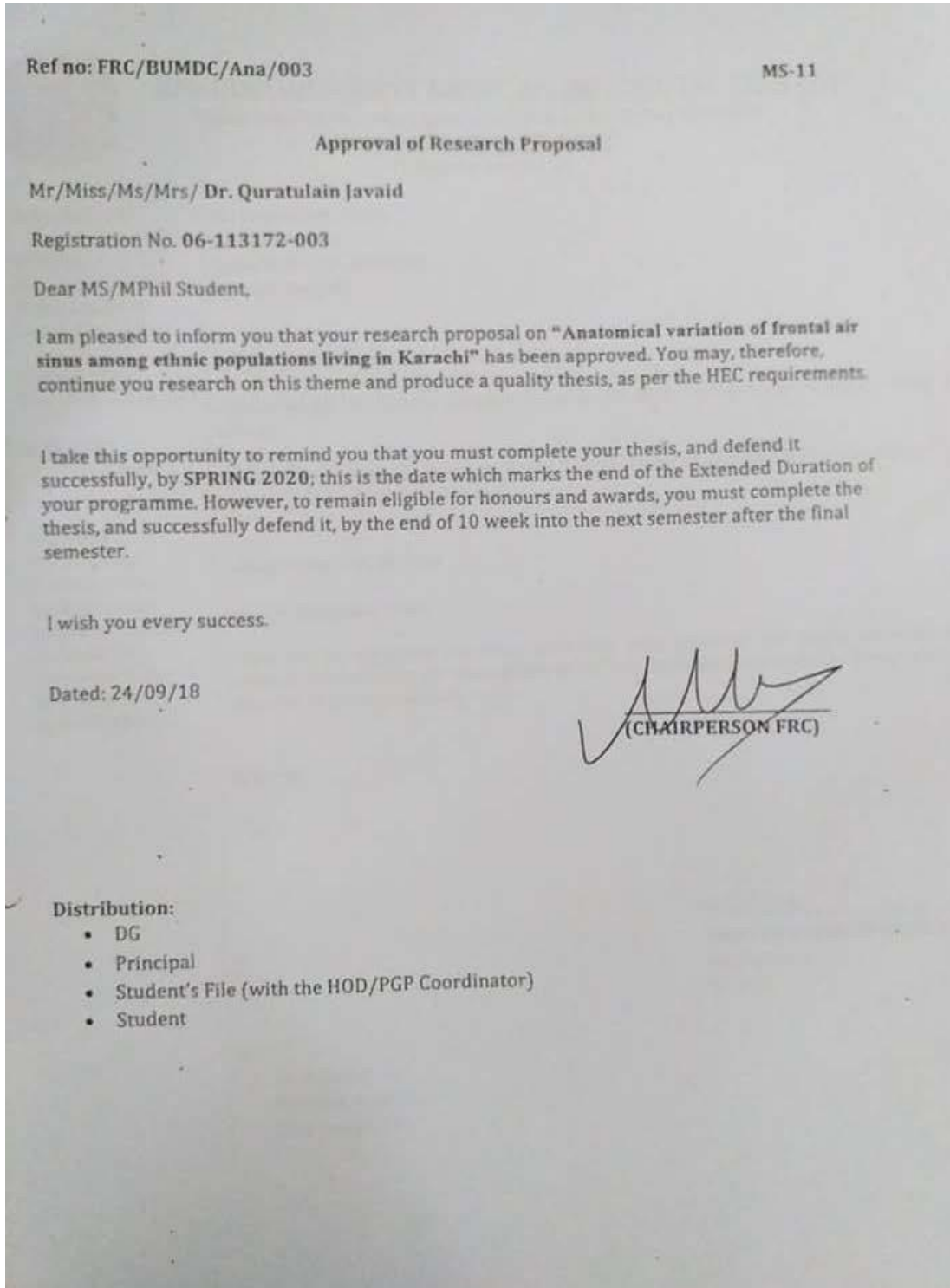
- Villarreal, R., Wrobel, B. B., Macias-Valle, L. F., Davis, G. E., Prihoda, T. J., Luong, A.U.,... & Clark, D.W. (2019). International assessment of inter and intra rater reliability of the International Frontal Sinus Anatomy Classification system. *International Forum of Allergy & Rhinology*, 9(1),39-45.
- Viner, M. (2018). *New Perspectives in Forensic Human Skeletal Identification*. Academic Press.
- Viner, M. D., & Robson, J. (2017).Post-Mortem Forensic Dental Radiography-a review of current techniques and future developments. *Journal of Forensic Radiology and Imaging*, 8, 22-37.
- Wallis, A., & Donald, P. J. (1988). Frontal sinus fractures: a review of 72 cases. *The Laryngoscope*, 98(6), 593-598.
- Watson, J. M. (2018). Positive Identification via Frontal Sinus Morphology: A Geographic Information Systems (GIS) Approach (Master's thesis). Retrieved from <https://trace.tennessee.edu/utkgradthes/5348>.
- Wiersema, J. M. (2016). Evolution of forensic anthropological methods of identification. *Academic Forensic Pathology*, 6(3), 361-369.
- Xavier, T. A., Terada, A. S. S. D., & da Silva, R. H. A. (2015). Forensic application of the frontal and maxillary sinuses: A literature review. *Journal of Forensic Radiology and Imaging*, 3(2), 105-110.
- Yazici,D.(2019).The effect of frontal sinus pneumatization on anatomic variants of paranasal sinuses. *European Archives of Oto-Rhino-Laryngology*,4,1-8.
- Yoshino, M., Miyasaka, S., Sato, H., & Seta, S. (1987). Classification system of frontal sinus patterns by radiography. Its application to identification of unknown skeletal remains. *Forensic Science International*, 34(4), 289-299.
- Zha, Y., Lv, W., Gao, Y. L., Zhu, Z. Z., & Gao, Z. Q. (2018). Design of cross-sectional anatomical model focused on drainage pathways of paranasal sinuses. *Journal of Clinical Otorhinolaryngology, Head, and Neck Surgery*, 32(9), 683-686.

Zhanna, S., Dzmitry, V., & Anzhelika B. (2019). The Pneumatisation of the Maxillary and Frontal Sinuses of Human. *EC Clinical and Experimental Anatomy*, 2(1), 14-16.



Zin, T.T., Ishigami, R., Shinkawa, N., & Nishii, R. (2018). *Use of Computed Tomography and Radiography Imaging in Person Identification*. Paper presented at International Multi Conference of Engineers and Computer Scientists. Singapore, Springer.

7.2 APPENDICES

(A) FRC Approval letter



(B) ERC Approval Letter (BUMDC)

	BAHRIA UNIVERSITY MEDICAL AND DENTAL COLLEGE Defence phase II, Sailor Street, adjacent to PNS Shifa, Karachi. Tel: 021-35319491-9 ETHICAL REVIEW COMMITTEE LETTER OF APPROVAL
Date: 01.10.18	Dr. Quratulain Javaid Senior Lecturer Department of Anatomy BUMDC-Karachi
PATRON Prof. Asad Ullah Khan Principal & Dean Health Sciences(BU)	Subject: Institutional Approval of research study
CHAIRPERSON Prof. Ambreen Usmani	Title of Study: Anatomical Variation of Frontal Air Sinus Among Ethnic Population Living In Karachi.
SECRETARY Prof Reza H Syed	Principal Investigator: Dr. Quratulain Javaid, Senior Lecturer Department of Anatomy, Bahria University Medical and Dental College.
MEMBERS Prof M Alamgir Prof Anis Jafarey Ms Nighat Huda Surg Cdre Amir Ejaz Ms Shabina Arif Mr M Amir Sultan Surg Lt Cdr Farah Surg Lt Cdr Sadia	Reference No: ERC 46/2018 Dear Dr. Quratulain Javaid Thank you for submitting the above mentioned study proposal. ERC Bahria University has reviewed this project in the meeting held on 24 th -Sep-2018 and gives approval. Kindly notify us when the research is complete.
	Regards,
	 PROF DR AMBREEN USMANI Chairperson BUMDC
	Cc: DG-BUMDC Principal BUMDC Chairperson ERC

ERC Approval Letter (JPMC)

NO.F.2-81/2018-GENL/ ²²⁶⁴ /JPMC
GOVERNMENT OF SINDH
JINNAH POSTGRADUATE MEDICAL CENTRE
KARACHI.75510.


Dated the 18/8/2018

Dr. Quratulain Javaid
M.Phil Anatomy Student
Senior Lecturer
Anatomy Department
Bahria University Medical & Dental College
DHA Phase-II
Karachi.

Subject: Anatomical variation of frontal air sinus among ethnic populations living in Karachi.

With reference to your application / letter dated 5th July, 2018, on the subject noted above and to say that the Institutional Review Board has approved your subject proposal.

Prof. Tariq Mehmood, Head Department of Radiology of this Centre in the co-supervisor of this study.


Prof. A.R. Jamali
Head of Department Orthopaedic Surgery and
Chairman Institutional Review Board Committee
JPMC, Karachi.

Copy forwarded for information and necessary action to:

- Prof. Tariq Mehmood, Head Department of Radiology (co-Supervisor), JPMC, Karachi.

(C) Consent Form (English version)

INFORMED CONSENT FORM

You are giving consent to participate voluntarily and at your own will in this research, 'Anatomical variations of frontal air sinus among ethnic populations living in Karachi.' The project aims to measure the frontal air sinuses by radiography.

The procedure involves the usage of X-ray films. There are no common side effects from sinus X-ray. The patient may feel some discomfort in the positioning of the head and neck, but will have no complications.

You have been explained in detail the nature and significance of participating in the research project and you understand the provided explanation.

You have been told that the findings of your disease and data will be kept strictly confidential and will be used for the benefit of the community, publications and paper presentations.

You have been told that the radiographs will be used for measuring the frontal sinuses. For this purpose you fully agree to allow your radiographs to be used for the research in the beginning, end or whenever required in between during the study.

You also agree to give all relevant information needed in full and to the best of your knowledge to the researcher. It is clarified to you that no incentive will be provided to you for participating in the study. You will have the right to with draw from the study any time.

You are advised to contact Dr.Quratulain on mobile number 0333-3764323 or visit JPMC in case of any query/emergency.

Name of study subject: S/O,

D/o, W/o Signature / thumb impression of the study participant:

Name of researcher:

Signature of the researcher:

Date:

Consent Form (Urdu version)

رضامندی فارم

آپ رضا کارانہ طور پر اور اپنی مرضی سے اس ریسرچ میں شامل ہونے پر رضامندی ظاہر کر رہے ہیں۔ جس کا مضمون ہے

انٹو میکل ویر ہیٹن آف فرنٹل ایر سائینس امنگ اینٹھنک پاپولیشن آف کراچی

اس پروجیکٹ کا مقصد ریڈیو گرافی کے ذریعہ فرنٹل ایر سائینس کی پیمائش کرنا ہے۔

اس طریقہ کار میں ایکس رے لٹھروں کا استعمال شامل ہے۔ عام طور پر سائینس ایکس رے کے ذیلی اثرات نہیں ہوتے۔ مریض کو اور گردن کو پوزیشن میں رکھتے کھجے آرامی ہو سکتی ہے لیکن اس میں کوئی پیچیدگی نہیں ہوتی۔

آپ کو اس ریسرچ پر وجہت میں شمولیت کی نوعیت اور اہمیت تفصیل سے بتادی گئی ہے اور آپ نے فرام کر دیا ہے اور وضاحت کو سمجھا لیا ہے۔

آپ کو بتا دیا گیا ہے کہ آپ کی بیماری سے متعلق معلومات اور اندازہ کار عمل پورے طور پر خفیہ رکھے جائیں گے اور انہیں کوئی مفاد نہ منگوانے کی تہیاری اور پیشکش میں استعمال کیا جائے گا۔

آپ کو بتا دیا گیا ہے کہ ریڈیو گرافی فرنٹل سائینس کی پیمائش کے لیے استعمال کیے جائیں گے۔ اس مقصد کے لیے آپ اپنے ریڈیو گراف کو اسٹڈی کے آغاز اختتام یا درمیان میں جب بھی ضرورت ہو کر سیرنگ کے لیے استعمال کی اجازت دینے پر پوری طرح رضامند ہیں۔

آپ تحقیق کنندہ کو متعلقہ معلومات جو ضروری ہوں، عمل اور اپنے علم کے مطابق دینے پر بھی رضامند ہیں۔ یہ آپ پر واضح کر دیا گیا ہے کہ اس اسٹڈی میں شامل ہونے کا کوئی معاوضہ نہیں ملے گا۔ آپ کو پتہ ہے کہ کسی بھی وقت اس اسٹڈی سے علیحدگی اختیار کر سکتے ہیں۔

آپ کو مشورہ دیا جاتا ہے کہ کوئی بھی سوال ریڈیو صورت میں ڈاکٹر ۱۹ اے اے سے موبائل نمبر 0333-3764323 پر رابطہ کریں یا جناح ہوسٹ گریجویٹ میڈیکل سینٹر نشتر لادین

مریض کا نام _____ والد یا شوہر کا نام _____

مطالعہ میں شرکت کرنے والے کے دستخط یا غلطی کا نشان _____

تحقیق کنندہ کا نام: ڈاکٹر ۱۹ اے اے

تحقیق کنندہ کے دستخط _____

تاریخ _____

(D) Subject Evaluation Proforma

SUBJECT EVALUATION PROFORMA

CODE NUMBER:

NAME	
AGE	
SEX	
ETHNICITY	

ANATOMICAL DATA – FRONTAL SINUSES

	WIDTH (cm) G	HEIGHT (cm) C
RIGHT FRONTAL SINUS		

	WIDTH (cm) I	HEIGHT (cm) E
LEFT FRONTAL SINUS		

	RIGHT AREA	LEFT AREA
FRONTAL SINUS AREA (cm²)		

Additional findings: -----

Questionnaire

Study Questionnaire



Code no:

Patient's name	
Age	
Sex	
Address	
Phone number	
Ethnicity	
Profession	

	Yes*	No
Are you having paranasal sinus disease symptoms (discharge from nose, nasal obstruction, reduced sense of smell, swelling around, eyes, cheek, nose etc.)		
Did you ever have any paranasal surgery?		
Did you ever have any injury/trauma to head?		
Are you pregnant?		

* Will be excluded from the study

(E) Hospital card

 جناح پوسٹ گریجویٹ میڈیکل سینٹر کراچی 

JINNAH POST GRADUATE MEDICAL CENTRE
Rafiqi Shaheed Road, Karachi-75510,
Ph. : 9201300 Ext. : 2402, 2262, 2263
E-mail: radiologyjpmc@hotmail.com

Token No.									
Date									
No. of Film									
Procedure									
Name									
Age									

DEPARTMENT OF RADIOLOGY

JINNAH POSTGRADUATE MEDICAL CENTRE KARACHI
Surgical/Nose & Throat/Eye/Medical
O.P.D. SLIP

Number _____ Dated _____
Name of Patient _____ S.O./D/O./W/O. _____
Age _____ Sex _____ Disease _____

Return Visit	Treatment

JPMC
MON WED FRI

(F) Turnitin Plagiarism Check Report

ANATOMICAL VARIATIONS OF FRONTAL AIR SINUS AMONG ETHNIC POPULATIONS LIVING IN KARACHI			
7 %	1 %	2 %	4 %
SIMILARITY INDEX	INTERNET SOURCES	PUBLICATIONS	STUDENT PAPERS
PRIMARY SOURCES			
1	Submitted to University of KwaZulu-Natal Student Paper		2 %
2	www.jofamericanscience.org Internet Source		1 %
3	Suleyman Kutalmış Buyuk, Ahmet Karaman, Yasin Yasa. "Association between frontal sinus morphology and craniofacial parameters: A forensic view", Journal of Forensic and Legal Medicine, 2017 Publication		1 %
4	Submitted to Universiti Sains Malaysia Student Paper		<1 %
5	Suleyman Kutalmış Buyuk, Huseyin Simsek, Ahmet Karaman. "The relationship between frontal sinus morphology and skeletal maturation", Folia Morphologica, 2015 Publication		<1 %
6	Submitted to University of Edinburgh Student Paper		<1 %

