

## MRI An Imaging Tool To Evaluate Cerebral Changes In Victims Of Heat Stroke Presenting With Cerebral Symptoms

Rahila Usman, Nabeel Humayaun Hassan, Saad Ahmed Jilani

### ABSTRACT:

Heat stroke usually presents as medical emergency that causes altered cerebral status and deterioration of multiple organ functions. Heat stroke leads to many different physiological changes within the body, some of which result in neurologic dysfunction. The imaging characteristics of neurological changes of heat stroke are not well documented in literature although the pathophysiologic mechanism of neuronal damage is fairly well understood. We conducted a study to evaluate the imaging appearances of human brain after heat stroke on MRI presented with cerebral symptoms.

**Material and methods:** The retrospective study conducted in radiology department of Ziauddin university hospital from May 2015 till July 2016. All the patients with heat stroke presented with neurological deficit were underwent MRI brain, evaluated by two senior radiologists.

**Results:** 56 patients were included in study, 12 female and 44 male, all patients had clinical symptoms of fever and most of them had additional symptoms of altered level of consciousness. Out of 54 patients, 8 patients had normal MRI brain. 6 patients presented with bilaterally symmetrical hyperintense signals on T2WI in thalami and basal ganglia. 2 patients demonstrated focal high signal intensity in pons representing pontine myelinosis, rest of the patients presented with cerebral or cerebellar infarcts.

**Conclusion:** Many cerebral lesions can result as cerebral damage of heat stroke which includes cerebral infarct, white matter changes, haemorrhages and inflammatory reactions, in these clinical scenarios MRI would be imaging modality of choice to evaluate the disease pattern.

**Keyword:** Heat stroke, brain lesions, ischemia.

### INTRODUCTION:

Heat stroke is characterized by an elevated core body temperature over 40°C. Heat stroke is potentially a life-threatening condition and usually presents as medical emergency that causes altered cerebral status and deterioration of multiple organ functions (1-2). Heat stroke leads to cerebral damage due to its exceptional susceptibility to injury. Neurologic abnormalities include confusion, seizures, or altered mental status. Several pathophysiological mechanisms are involved in causing cerebral injury like, altered haemostasis resulting in small vessel ischemia and can present as diffusion restriction on MRI, direct injuriousness effect of heat to certain cell types which contain abundant amount of heat shock proteins (e.g., Purkinje cells of cerebellum), release of interleukin 1 generating inflammation and apoptosis, leakage of cerebrospinal fluid

as a result of cytokine secretion serving to prolong vasogenic ischemia resulting in ischemic changes (2). The most vulnerable organs to heat damage are cerebellum, basal ganglia, hypothalamus and limbic system (3, 6). In addition thalamus, cerebral cortex, brain stem, and anterior horn cells of spinal cord are also susceptible to heat injury.

Due to global climatic change, severe heat wave with temperatures as high as 49 °C (120 °F) struck Sindh province and its capital city, Karachi in June 2015 and 2016. A large number of people became the victim of heat wave. We conducted a study to evaluate the imaging appearances of human brain after heat stroke on MRI presented with cerebral symptoms.

### MATERIAL AND METHODS:

This is a retrospective review done in radiology department at ziauddin university hospital from May 2015 to July 2016. As the institute is a tertiary care centre and present in the centre of city, so during the period of heat wave, a large number of patients with heat stroke were shunted to the hospital. All clinically diagnosed patients of heat stroke having neurological symptoms were underwent MRI brain. MRI examination was conducted between days 0 to fifth day of admission depending upon the evolution of neurological symptoms. MRI findings were evaluated by two senior radiologist having experience of more than five years. Total 56 patients were enrolled in study; patients of either gender were included in study. All clinically diagnosed patients of heat stroke having neurological symptoms were

#### Rahila Usman.

Assistant professor, Department of Radiology at Dow University Hospital  
Email: docrahila@yahoo.com

#### Nabeel Humayaun Hassan.

Assistant professor, Department of ENT and head and neck surgery at Lyari journal hospital.

#### Saad Ahmed Jilani

Assistant professor, Department of radiology at Ziauddin university hospital

Received: 07-06-2018

Accepted: 25-09-2018

underwent MRI brain for possible imaging findings. Paediatric age group patients of below 14 years were excluded from study. After taking informed consent from all patients and MRI brain was performed with 1.5 Tesla scanner. Typical brain protocol including axial T1-weighted spin echo, axial and sagittal T2-weighted spin echo, axial, coronal and sagittal contrast enhanced T1-weighted images (as required), coronal FLAIR images were obtained. DW and ADC imaging was performed in all patients using a single-shot echo-planar (EPI) pulse sequence (TR/TE= 3000/90 ms), with matrices of 128×128 and a section-thickness of 5 mm with a 1-mm intersection gap.

**RESULTS:**

Out of 56 patients, 12 (21.4%) were female and 44 (78.5%) were males, with mean age of 36 years. Almost all of the patients presented with high grade fever among them 32 (57%) developed altered level of consciousness, 16 (28.5%) patients has additional symptom of seizures and 4 (7.1%) patients had delirium.

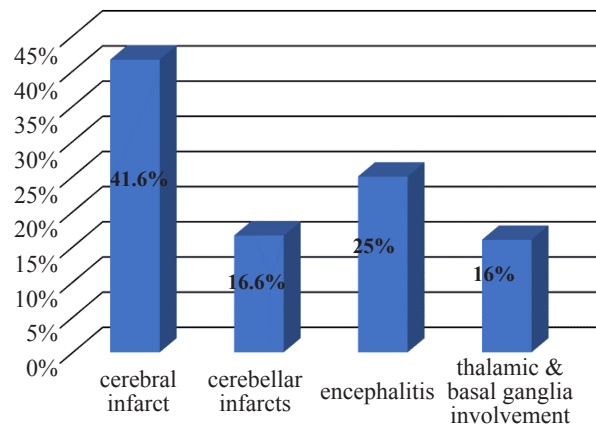
On evaluating the MRI of affected patients 8 (14%) patients had absolutely normal MRI brain whereas bilaterally symmetrical hyperintense foci in thalami and basal ganglia were observed in 6 (10.7%) patients, focal high signal intensity in pons on T2WI was seen in 2 (3.5%) patients, acute cerebral and cerebellar infarcts showing diffusion restriction was present in 12 (21.4%) and 6 (10.7%) patients respectively. Foci of punctate haemorrhages showing signal drop out on SWI were present in 8 (14.2%) patients. Areas of diffusion restriction in hippocampi were appreciated in 5 (8.9%) patients and 9 (16%) patients developed encephalitis during hospital stay. Out of 56 patients 12 (21.4%) patients were unable to survive. Among non survivors 8 (66.6%) were males whereas (33.3%) were female. Large cerebral infarcts were the pronounced imaging pathology in non survivors seen in 5 (41.6%) cases, followed by encephalitis in 25% (n=3) cases. Whereas rest of the non survivors had cerebellar infarcts in 16.6% (n=2) cases, basal ganglia and thalamic involvement in 16.6% (n=2) cases.

**DISCUSSION:**

Several pathophysiological mechanisms are involved in causing cerebral injury. The heat stress causes diversion of blood from the splanchnic vessels to disseminate in periphery vasculature in order to disintegrate heat effect. As a result of heat stroke there is increase release of heat shock proteins with increase in production of cytokines (2) resulting in splanchnic ischemia which may lead to cerebral infarct which can present as areas of diffusion restriction on DWI/ADC sequences. The body will develop severe inflammatory response and sepsis like reaction in consequence of endotoxin release. Many mechanisms has been proposed to cause brain damage by heat stress. Increased cytokines release like interleukin 1 may lead to apoptosis or cell death, In addition increase cytokines can

MRI FINDINGS	FREQUENCY
Normal MRI brain	14.2% (8/56)
Hyperintense areas in thalami and basal ganglia	10.7% (6/56)
High signal in pons on T2WI	3.5% (2/56)
Diffusion restriction in cerebral cortices	21.4% (12/56)
Diffusion restriction in cerebellar hemisphere	10.7% (6/56)
Punctate foci of hemorrhages	14.2% (8/56)
Areas of Diffusion restriction in hippocampi	8.9% (5/56)
Encephalitis	16.0% (9/56)

Tables: Findings on MRI brain in victims of heat stroke:



MRI features in non-survivor:

result in damage to blood-brain barrier or blood-cerebrospinal fluid (CSF) barrier which leads to vasogenic oedema (8,9) which may result in brain ischemia. During research on rabbit cerebellum the results showed that Purkinje cells may have a key role in thermal injury repair. In cerebellum heat stress cause direct damage to the purkinje serving to hypoxic ischemic injury and may lead to cerebellar symptoms (8).

MRI plays key role in detection of neurological abnormalities caused by heat stroke. MRI findings include, cerebral infarcts, lesions in dentate nuclei, haemorrhages, lesions in cerebellar hemispheres and cerebellar peduncles [5]. The results of this study are in consensus with previous studies.

A case report from 2003 of a patient with heat stroke revealed bilateral external capsule, bilateral putamen, and a bilateral cerebellar process with haemorrhagic deposits on T2- and T1WI and some enhancement on gadolinium images. The authors proposed that small vessel ischemia was the leading cause of imaging appearances (10).

A study conducted on 9 patients by Jun Li et al in 2015 revealed punctate haemorrhage in brain stem evident by areas of signal susceptibility on SWI, diffusion restriction on DWI/ADC images in the left centrum semiovale, symmetric lesions in cerebellar peduncles and acute massive cerebral infarction. Similar spectrum of imaging appearances

was detected in all patients enrolled in the study (11).

This study is a valuable literature as limited number of cases was reported in the literature that describes the imaging appearances of cerebral damage as a result of heat stress. Heat stroke has generally reported in case reports or small case series. But there are several limitations to this study like the MRI findings of survivors were not followed, the sample size was small and paediatric age group patients were excluded from the study.

#### REFERENCES:

1. Bouchama A, Knochel JP. Heatstroke. *N Engl J Med.* 2002;346(25):A978–1988. [PubMed]
2. Yaqub B, Al Deeb S. Heat strokes: aetiopathogenesis, neurological characteristics, treatment and outcome. *J Neurol Sci.* 1998;156(2):144–151
3. Lee JS, Choi JC, Kang SY, Kang JH, Park JK. Heat stroke: increased signal intensity in the bilateral cerebellar dentate nuclei and splenium on diffusion-weighted MR imaging. *AJNR Am J Neuroradiol* 2009; 30(4): E58.
4. Albukrek D, Bakon M, Moran DS, Faibel M, Epstein Y. Heat-stroke-induced cerebellar atrophy: clinical course, CT and MRI findings. *Neuroradiology* 1997; 39(3): 195-7.
5. Murcia-Gubianas C, Valls-Masot L, Rognoni-AMRlein G. Brain magnetic resonance imaging in heat stroke. *Med Intensiva* 2012; 36(7): 526.
6. Mahajan S, Schucany WG. Symmetric bilateral caudate, hippocampal, cerebellar, and subcortical white matter MRI abnormalities in an adult patient with heat stroke. *Proc (Bayl Univ Med Cent)* 2008; 21(4): 433-6.
7. Li J, Zhang X, Wang B, Zou Z, Wang P, Xia J, *et al.* Diffusion tensor imaging of the cerebellum in patients after heat stroke. *Acta Neurol Belg* 2014;115:147-50.
8. Li J, Zhang X, Wang B, Zou Z, Li H, Wang P, *et al.* Multivoxel proton magnetic resonance spectroscopy in heat stroke. *Clin Radiol* 2015;70:37-41.
9. Zhang XY, Li J. Susceptibility-weighted imaging in heat stroke. *PLoS One* 2014; 9(8): e105247
10. Murcia-Gubianas C, Valls-Masot L, Rognoni-AMRlein G. Brain magnetic resonance imaging in heat stroke. *Med Intensiva* 2012; 36(7): 526.
11. MRI findings in human brain after heat stroke, Jun Li1, Xueyan Zhang2, Bin Wang2, Junzu Geng, *Journal of Nature and Science*, Vol.1, No.2, e42, 2015
12. Rodriguez-Fernandez M, Grosman B, Yuraszcek TM, *et al.* Modeling the intra-and extracellular cytokine signaling pathway under heatstroke in the liver. *PLoS One.*2013;8(9):e73393.
13. Squizzato A, Hunt BJ, Kinasewitz GT. Supportive management strategies for disseminated intravascular coagulation. An international consensus. *Thromb Haemost.* 2016;115:896–900.
14. McLaughlin CT, Kane AG, Auber AE. MR Imaging of Heat Stroke: External Capsule
15. and Thalamic T1 Shortening and Cerebellar Injury. *American Journal of Neuroradiology.*2003;24(7):1372.
16. Ookura R, Shiro Y, Takai T, Okamoto M, Ogata M. Diffusion-weighted Magnetic Resonance Imaging of a Severe Heat Stroke Patient Complicated with Severe Cerebellar Ataxia. *Internal Medicine.* 2009;48(12):1105-8
17. Sudhakar PJ, Al-Hashimi H. Bilateral hippocampal hyperintensities: a new finding in MR imaging of heat stroke. *Pediatric Radiology.* 2007;37(12):1289-91.
18. Fushimi Y, Taki H, Kawai H, Togashi K. *Clin Radiol.* Abnormal hyperintensity in cerebellar efferent pathways on diffusion-weighted imaging in a patient with heat stroke. 2012 Apr; 67(4):389-92. Epub 2011 Nov 25.
19. Li J, Zhang XY, Zou ZM, Wang B, Xia JK Abnormal hyperintensity in cerebellar efferent pathways on diffusion-weighted imaging in a patient with heat stroke.
20. Larson PE, Kerr AB, Chen AP, *et al.* Multiband excitation pulses for hyperpolarized <sup>13</sup>C dynamic chemical-shift imaging. *J Magn Reson.* 2008;194(1):121–127
21. Cheng Q, Xu X, Zu Q, Lu S, Yu J, Liu X, Wang B, Shi H, Teng G, Liu S. Exp Ther High b value DWI in evaluation of the hyperacute cerebral ischemia at 3T: A comparative study in an embolic canine stroke model. *Med.* 2016; 12(2):951-956. Epub 2016 May 27.
22. Hong JY, Lai YC, Chang CY, Chang SC, Tang GJ. Successful treatment of severe heatstroke with therapeutic hypothermia by a noninvasive external cooling system. *Ann Emerg Med.* 2012; 59(6):491-3.
23. Lee BC, Kim JY, Choi SH, Yoon YH Use of an external-cooling device for the treatment of heat stroke. *Clin Exp Emerg Med.* 2014 Sep; 1(1):62-64. Epub 2014 Sep 30
24. Muccio CF, De Blasio E, Venditto M, Esposito G, Tassi R, Cerase A. Heat-stroke in an epileptic patient treated by topiramate: follow-up by magnetic resonance imaging including diffusion-weighted imaging with apparent diffusion coefficient measure. *Clin Neurol Neurosurg.* 2013;115(8):1558-60.
25. Fuse A, Yamashiro K, Oji Y, Furuya T, Noda K, Hattori N, *et al.* Reversible focal cerebral cortical lesions in a patient with heat stroke. *Intern Med.* 2013;52(3):377-80.

