

Restoration of Germinal Epithelium with Usage of Antioxidant Oils in Phenytoin Induced Testicular Toxicity: A Comparative Study in Rats

Khalique-ur-Rehman, Syed Muhammad Masood Ali, Khalid Shehzad, Sonia Khan, Sarah Sughra, Hina Khan

ABSTRACT:

Objective: To evaluate antioxidant effect of Virgin Coconut Oil (VCO) and Corn Oil (CO) on germinal thickness (GT) in rats induced with phenytoin toxicity.

Study design and setting: An Experimental Longitudinal study was done at AL-Tibri Medical College and Hospital Isra University Karachi Campus.

Methodology: 28 male albino rats were selected and were divided into 4 groups each consisting of 7 rats. Group A received normal saline solution only, Group B received 10mg/kg/body weight of Phenytoin, Group C received VCO+ Phenytoin, and Group D received CO+ Phenytoin. Animals were euthanized on the 4th, 5th, & 6th week and tissue sample was collected for measuring GT using stage micrometer. Data was analyzed using SPSS 20.0. All values were expressed as mean \pm S.D., groups compared using One way ANOVA followed by Post hoc Tukey's test with p-value <0.05.

Results: on 4th, 5th, & 6th week significant difference in germinal thickness was seen in Group A comparing it against the phenytoin group B (P-value: <0.001, <0.001, & 0.001). On 4th, 5th, & 6th week significant difference in GT was seen in Group C (VCO + Phenytoin) comparing it against the phenytoin group B (P-value: <0.001, <0.001, & <0.001). No significant difference in germinal thickness was seen on 4th, 5th, & 6th week was seen when Group D (CO + Phenytoin) was compared to Group B (p-value: 0.551, 0.954, & 0.931).

Conclusion: Virgin Coconut Oil can reduce the negative effect caused by phenytoin induced toxicity by preventing thinning of the germinal layer.

Keywords: Coconut Oil, Phenytoin, Corn Oil, Germinal Thickness

How to cite this Article:

Rehman KU, Ali SMM, Khalid S. Khan S, Sughra S, Khan H. Restoration of Germinal Epithelium with Usage of Antioxidant Oils in Phenytoin Induced Testicular Toxicity: A Comparative Study in Rats. J Bahria Uni Med Dental Coll. 2023;13(3):162-6 DOI: <https://doi.org/10.51985/JBUMDC2021083>

This is an Open Access article distributed under the terms of the Creative Commons Attribution Non Commercial License (<http://creativecommons.org/licenses/by-nc/4.0>) which permits unrestricted non commercial use, distribution and reproduction in any medium, provided the original work is properly cited.

Khalique-ur-Rehman

Assistant Professor, Department of Anatomy
Chandka Medical College Shaheed Benazir Butto Medical
University Larkana
Email: --

Syed Muhammad Masood Ali

Associate Professor, Department of Pharmacology
Al-Tibri Medical College, Isra University Karachi Campus
Email: drmasoodali8@yahoo.com

Khalid Shehzad

Associate Professor, Department of Anatomy
Liaquat College of Medicine and Dentistry, Karachi
Email: drkhalidsh@yahoo.com

Sonia Khan

Assistant Professor, Department of Pharmacology
Al-Tibri Medical College, Isra University Karachi Campus
Email: drsonia.azeem@gmail.com

Sarah Sughra

Assistant Professor, Department of Anatomy
Sir Syed College of Medical Sciences for Girls, Karachi Clifton
Email: sarahsughra1972@gmail.com

Hina Khan

Professor / Deputy Director Research & PG Affairs, Department
of Anatomy
Al-Tibri Medical College, Isra University Karachi Campus
Email: drhinasalman@gmail.com

Received: 12 Oct 2021
Accepted: 20 Jun 2023

INTRODUCTION:

Anti-seizure medications play a vital role in preventing seizures of different types. The choice of which seizure medication is to be given to the patient, mostly depends on the type of seizure the patient is suffering from such as tonic-clonic or myoclonic seizure, as well as the preexisting comorbid conditions the patient already has. All of the anti-seizure medications work to reduce/inhibit the neuronal firing by working with various types of neurotransmitters and ionic channels. Most of the first line anti-seizure drugs work by reducing the metabolism of cytochrome P450 enzymes and also play a part in the induction or inhibition of the enzyme. Since its inception way back in 1908, phenytoin has become the go to drug for treating generalized seizures in populations comprehensively. Furthermore, it is the most studied drug of its class¹. Phenytoin binds to the sodium voltage-gated channels while these ionic channels are in-active state to further increase the inactivity time of these voltage channels. This then consequently translates to a reduction in the frequency with which the nerves can propagate action potentials in the nervous system. It is important that this drug is well studied as it is the most widely used drug for treating anti-convulsants. However, there is a lot of potential for this drug; another more worrying

reason for so much research being placed into this drug is due to its multi-systemic side effects endured by the patients receiving this. The reason for phenytoin inducing so much toxicity in the body is mainly due to its narrow therapeutic index². The toxic adverse effects cause by phenytoin included aplastic anemia, leukemia, agranulocytosis, leukemia, gingival hyperplasia, and other neurological deficits³⁻⁵. Studies have also shown that anti-epileptic medications such as phenytoin can also have a side effect on abnormal sperm morphology, redundant sperm count, and a reduction in testicular volume⁶. These issues can ultimately then result in infertility and impotence causing a significant negative impact on the social lives of many men. Fortunately, this potential life changing side effect can be navigated by providing an antioxidant effect which then reduces the number of Reactive Oxygen Species (ROS). ROS are free radical generated in the body due to accumulation of oxidative stresses. The buildup of oxidative stress lays the groundwork for many disorders including male impotence⁷. Antioxidants reduce the harmful effects caused by free radicals that will eventually diminish oxidative stress⁸. Antioxidants can be nutrients or in the form of enzymes. Antioxidants are said to play a role in preventing the onset of many chronic diseases such as stroke, cardiovascular diseases, cancer, diabetes, Alzheimer's diseases, cataracts and Rheumatoid arthritis⁹. Among the many antioxidants at our disposal, virgin coconut oil (VCO) and Corn Oil (CO) are some of the oils that exhibit antioxidant effects, with previous studies highlighting their potential benefits¹⁰. VCO and CO have shown good effect as antioxidant in many body systems and against other therapeutic agents. To see if it can have the same effect on the male reproductive system in the presence of phenytoin, a study was conducted to assess the germinal layer thickness in rats with phenytoin induced toxicity and intervention using virgin coconut and corn antioxidant oils.

METHODOLOGY:

This experimental study was designed and conducted in the anatomy department of AL-Tibri Medical College and Hospital Isra University Karachi Campus. The study was approved by the respected institutional review board (IRB)(IERC/ATMC/21/78) for ethical approval which was granted. The span of the study lasted for a period 6 months. For this study we selected 48 Healthy Male Albino rats weighing 150-250 grams each which were acquired from the institution's animal house. No unhealthy Male albino rat or any rat that weight between below 150 or above 250 was included in this study. All the animals were weighted with an electronic weight machine and their health status evaluated by a Vet. Phenytoin was purchased from a nearby pharmacy. The acquired rats were then divided into 4 groups each consisting of 12 rats each. For the study 21 male albino rats were acquired from the Animal Housing of the institution randomly. The allocation of the 48 male albino rats into the 4 intervention groups were also done randomly. The sample

size was calculated by using formula of "E" and the value of "E" lies between 10 and 20.

$E = \frac{\text{Total numbers of animals} - \text{total numbers of groups}}{\text{One group is control and other 3 experimental groups with 7 numbers of rats/group}}$ ¹¹. $E = (8 \times 4) - 4 = 32 - 4$, $E = 28$ (seven numbers of rats/group).

The subjects were separated and the following intervention was carried out in each group:

Group A: The control group received one unit of normal saline solution through an intra-peritoneal injection including a normal daily diet.

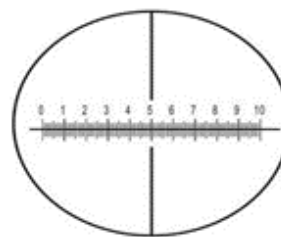
Group B: Received a dose of 10mg/kg/body weight of Phenytoin through an intra-peritoneal injection once every day.

Group C: Received 6.7ml of Virgin Coconut Oil along with a dose of 10mg/kg/body weight of Phenytoin through an intra-peritoneal injection once every day.

Group D: Received 2.5ml Corn Oil along with a dose of 10mg/kg/body weight of Phenytoin through an intra-peritoneal injection once every day.

All the subjects were kept under close observation, and separated into cages during which their diet was well regulated along with their light duration (12 hours dark and 12 hours light) also being kept constant. The animals were tagged and labeled so that they can be regularly identified. The animals were euthanized for the collection of the samples on the 4th, 5th, and 6th week of the study. This was done by first giving them anesthesia with ethanol and then producing a sterile incision using a scalpel blade sagittally in the abdominal wall from xiphisternum to pubic symphysis then both testes were removed. For measurement of the germinal layer thickness, tissue was then extracted from the testis and preserved in 10% formalin solution. The tissue was then process for slide preparation and staining. H&E stain were used for the tissue preparation. To measure the thickness of germinal epithelium, the stage micrometer along with a light microscope was used as shown in figure: 1. Data was analyzed by using the software statistical packages of social sciences (SPSS) version 20.0. All values were expressed as mean \pm S.D. The groups were compared by using One-way

Figure: 1 shown the stage micrometer



935 Micrometer
1 DIV = 0.1mm
0.1x100=10mm

ANOVA followed by Post hoc Tukey’s test and statistical significance was taken at $p < 0.05$.

RESULTS:

Table 1: Shows the comparison of the thickness of the germinal layer among different groups (um). Significant difference is seen in the 4th, 5th, and 6th week when Group B was compared with Group A and C ($p < 0.001$). Figure 2: Showing the mean thickness of germinal layer (um) among different groups.

DISCUSSION:

The aim of this study was to investigate whether antioxidant oils like virgin coconut oil and corn oil can provide a protective effect on the male reproductive system of rats by reducing the harmful effects caused by phenytoin, such as thinning of the germinal epithelium. The study aimed to assess whether the antioxidant properties of these oils can mitigate the detrimental impacts of phenytoin on the male reproductive system. The need for antioxidant agents that can reduce the free radical levels in various parts of the body is absolutely crucial and this effect can be seen in some oils. Corn Oil has been concluded to be a potent antioxidant agent from results of chemical assays¹². Another study on the body weight, biochemical, and haematological parameters have also proved the capability of corn oil has on the liver and kidneys of rats, further highlighting its antioxidant

proress¹³. Otuechere et al (2014) in a study conducted by him showed that coconut oil had a protective effects against the toxic nature of Trimethoprim-sulfamethoxazole (TMP-SMX) a broad spectrum antibiotic used to treat gram-positive and gram-negative aerobic infections induced a positive effect on the livers of rats. He used biochemical parameters in his study and demonstrated the restoring levels of total bilirubin, lactate dehydrogenase, and alkaline phosphatase and a subsequent increase in these parameters by 192%, 41%, and 67% respectively compared to the control values¹⁴. In another randomized control clinical trials it was seen that coconut oil even though enriched in saturated fatty acids in comparison to sunflower oil did not cause any change in the cardiovascular related risk factors over a 2 year period with the study finding no statistically significant difference in terms of cardiovascular event, biochemical, anthropometric, and vascular function¹⁵.

Infertility is a very serious issue not just in our society, but all around the world. It is very controversial and personal to a person and many individuals fail to discuss it openly or seek health care needs regarding this choosing to shy away from a problem which indeed does have competent medical management and treatment strategies. Seven percent of couples around the world are said to be infertile, and half of these couples are said to be infertile due to male related factors. The Pakistani population is unfortunately one in which the vast majority of them belong to a low-middle income background and aren’t well advised to seek treatment for their infertility. It has been reported that the prevalence of infertility is significant in the country, with a reported 22% having infertility and with primary infertility accounting for 4% of the total cases. Infertility just doesn’t have physical effects but as well as psychological trauma among women as the Pakistani society considers this as a failure on a social, emotional, and personal level. Awareness regarding the causes of infertility among the populations is inadequate, and emphasis need to be targeted towards fertility education, along with general public health campaigns to raise awareness regarding the causes, risk factors, and the general ways to overcome this issue and ultimately reducing the countrywide prevalence of the condition¹⁶.

Figure 2: Showing the mean thickness of germinal layer (um) among different groups

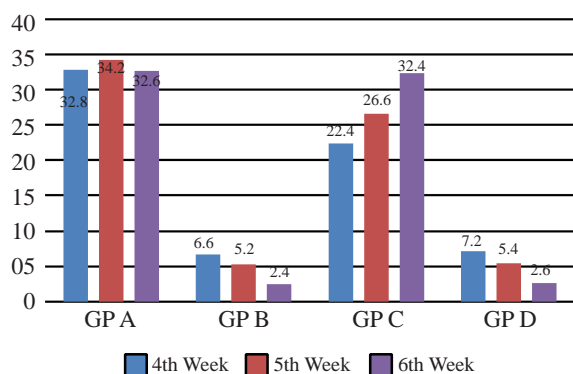


Table 1: Shows the thickness of the germinal epithelium layer being compared among different groups (um)

Weeks	Thickness of Germinal Layer (Experimental GP)	Groups	Thickness of Germinal Layer (Experimental GP)	Comparison of groups	P-Value
4 th week	B 6.6 ± 0.83	A	32.8 ± 1.51	B vs A	<0.001
		C	22.4 ± 1.14	B vs C	<0.001
		D	7.2 ± 1.14	B vs D	0.551
5 th week	B 5.2 ± 0.70	A	34.2 ± 1.51	B vs A	<0.001
		C	26.6 ± 1.30	B vs C	<0.001
		D	5.4 ± 0.83	B vs D	0.954
6 th week	B 2.4 ± 1.67	A	32.6 ± 1.67	B vs A	<0.001
		C	32.4 ± 1.58	B vs C	<0.001
		D	2.6 ± 0.70	B vs D	0.937

The infertility mentioned before is associated with the development of ROS species which include superoxide anions, hydrogen peroxide (H₂O₂), hydroxyl (·OH) and proxyl (·ROO) ¹⁷⁻¹⁸. Damage to the sperm by ROS is the number one cause of infertility in 30-80% of infertile male populations ¹⁹. The role of antioxidant system is crucial in reducing and coping with the excess generation of ROS²⁰. Anti-epileptic drugs are known for causing a negative effect on the sexual functions of male²¹. Our study was done to evaluate how the antioxidant effects of VCO and CO can reduce the toxicity induced by phenytoin. VCO showed significant difference in the germinal thickness when compared to the phenytoin induced group however CO wasn't an effective antioxidant agent, with the findings being similar to the phenytoin group in which there was a thinning of the germinal epithelium. Significant difference (P-value <0.05) was seen on the 4th, 5th, and 6th week when virgin coconut oil was compared to the group given phenytoin only with a germinal layer thickness of the virgin coconut oil group being

22.4 ± 1.14, 26.6 ± 1.30, and 32.4 ± 1.58 on the 4th, 5th, and 6th week respectively almost being equal to the control group A by the end of the study. This showed that with time surpassing VCO can actually increase the germinal layer thickness to almost normal levels even in the presence of phenytoin, a highly toxic substance to the reproductive system of the body. This shows the VCO has the potential to reduce harm to the male reproductive system that is caused by phenytoin. Ogedenbe et al (2016) conducted a study to show the mitigating effect of VCO extract on testicular injury following highly active anti-retroviral therapy (HAART), in this study he concludes that while there were derangements in parameters of testicular injury, adjunctive treatment of VCO following HAART did restore some function of the testes. Phenytoin induced group showed a reduction in the germinal layer thickness with the passage of time and so did the corn oil group. This finding was similar to another study that showed atrophy and massive thinning in the germinal layer of seminiferous tubules becoming more advance with the administration of phenytoin, furthermore also causing a percentage of total motile sperm decrease²². Studies have shown that men with epilepsy tend to experience greater amount of sexual dysfunction than men do in the general population²³. Olufunke et al (2011) also induced oxidative stresses using alcohol and observed changes in male germinal cells. He used VCO and CO and concluded that the groups in which VCO was used there was significantly higher levels of germinal cells that can be correlated to our study which studied germinal thickness. Furthermore his study showed that the administration of virgin coconut oil improved that antioxidant state by decreasing the levels of malondialdehyde (MDA) and altered the lipid profile status by decreasing the levels to near normal while also increasing the levels of testosterone, sperm count,

and motility²⁴. We can say that VCO like conclude and shown by other previous studies on different organs can also reduce the harmful effects of phenytoin induced toxicity. Other parameters have been evaluated such as tubular dimensions in previous studies in which the mean value of seminiferous tubules was increased significantly in groups in which antioxidant oils (virgin coconut oil and corn oil) were administered compared to a drastic decreased in the tubular diameter in which only phenytoin was administered²⁵. Other antioxidant agents can also be used to see how the potential restore function or how much they can reduce toxicity of phenytoin. Our study only demonstrated the effect of antioxidants on germinal thickness; however, other parameters could have been measured such as testicular weight, sperm motility, and sperm count. The study could have used other types of oils or antioxidant agents to assess the effects and urges others to do so in future studies to strengthen the literature. Other organs such as the liver should also be assessed on morphological, histological, and biochemical parameters thoroughly to assess how well antioxidant oils such as virgin coconut oil perform and if they can induce a hepatoprotective effect just like it did on the reproductive system of the male albino rats.

CONCLUSION:

Virgin Coconut oil and Coconut Oil were evaluated to assess their impact on the germinal layer thickness in the presence of phenytoin induced toxicity. Virgin coconut oil aided in reducing the toxic effect of phenytoin on the testes by preventing the thinning of the germinal layer in male albino rats by providing an antioxidant effect and reducing the free radical levels within the reproductive system.

Authors Contribution:

Khalique-ur-Rehman: Conception/ Data Analysis
Syed Muhammad Masood Ali: Drafting of Article
Khalid Shehzad: Interpretation of Data
Sonia Khan: Analysis
Sarah Sughra: Final Approval for Version
Hina Khan: Design

REFERENCES:

1. Fohner AE, Ranatunga DK, Thai KK, Lawson BL, Risch N, Oni-Orisan A, et al. Assessing the clinical impact of CYP2C9 pharmacogenetic variation on phenytoin prescribing practice and patient response in an integrated health system. *Pharmacogenet Genomics* [Internet]. 2019;29(8):192–9. Available from: <http://dx.doi.org/10.1097/FPC.0000000000000383>
2. Patocka J, Wu Q, Nepovimova E, Kuca K. Phenytoin-An anti-seizure drug: Overview of its chemistry, pharmacology and toxicology. *FCT*. 2020;142.
3. Hatahira H, Abe J, Hane Y, Matsui T, Sasaoka S, Motooka Y, et al. Drug-induced gingival hyperplasia: a retrospective study using spontaneous reporting system databases. *J Pharm Health Care Sci* [Internet]. 2017;3(1):19. Available from: <http://dx.doi.org/10.1186/s40780-017-0088-5>

4. Craig S. Phenytoin overdose complicated by prolonged intoxication and residual neurological deficits. *Emerg Med Australas* [Internet]. 2004;16(4):361–5. Available from: <http://dx.doi.org/10.1111/j.1742-6723.2004.00629.x>
5. Vijay P, Yeshwanth R, Bairy KL. Effect of phenytoin sodium on the biochemical parameters of reproductive function in male albino Wistar rats. *J Physiol Biomed Sci*. 2009;22:14–8.
6. Brezina PR, Yunus FN, Zhao Y. Effects of pharmaceutical medications on male fertility. *J Reprod Infertil*. 2012;13(1):3–11.
7. Bisht S, Faiq M, Tolahunase M, Dada R. Oxidative stress and male infertility. *Nat Rev Urol* [Internet]. 2017;14(8):470–85. Available from: <http://dx.doi.org/10.1038/nrurol.2017.69>
8. Adwas AA, Elsayed A, Azab AE, Quwaydir FA. Oxidative stress and antioxidant mechanisms in human body. *Journal of Applied Biotechnology & Bioengineering*. 2019;6(1):43–7.
9. Kumar S, Sharma S, Vasudeva N. Review on antioxidants and evaluation procedures. *Chin J Integ Med* [Internet]. 2017; Available from: <http://dx.doi.org/10.1007/s11655-017-2414-z>
10. Famurewa AC, Aja PM, Maduagwuna EK, Ekeleme-Egedigwe CA, Ufebe OG, Azubuike-Osu SO. Antioxidant and anti-inflammatory effects of virgin coconut oil supplementation abrogate acute chemotherapy oxidative nephrotoxicity induced by anticancer drug methotrexate in rats. *Biomed Pharmacother* [Internet]. 2017;96:905–11. Available from: <http://dx.doi.org/10.1016/j.biopha.2017.12.00>
11. Charan J, Biswas T. How to calculate sample size for different study designs in medical research? *Indian J Psychol Med* [Internet]. 2013;35(2):121–6. Available from: <http://dx.doi.org/10.4103/0253-7176.116232>
12. Zheng L, Jin J, Karrar E, Xie L, Huang J, Chang M, et al. Antioxidant activity evaluation of tocopherol through chemical assays, evaluation in stripped corn oil, and CAA assay. *Eur J Lipid Sci Technol* [Internet]. 2020;122(3):1900354. Available from: <http://dx.doi.org/10.1002/ejlt.201900354>
13. Mahmood NM, Hamad KR. The Study of Body Weight, Haematological and Serum Biochemical Parameters, Liver and Kidney Texture in Rats Fed Corn Oil. *ZANCO Journal of Pure and Applied Sciences*. 2017;29:76–86.
14. Otuechere CA, Madarikan G, Simisola T, Bankole O, Osho A. Virgin coconut oil protects against liver damage in albino rats challenged with the anti-folate combination, trimethoprim-sulfamethoxazole. *J Basic Clin Physiol Pharmacol* [Internet]. 2014;25(2):249–53. Available from: <http://dx.doi.org/10.1515/jbcpp-2013-0059>
15. Vijayakumar M, Vasudevan DM, Sundaram KR, Krishnan S, Vaidyanathan K, Nandakumar S, et al. A randomized study of coconut oil versus sunflower oil on cardiovascular risk factors in patients with stable coronary heart disease. *Indian Heart J* [Internet]. 2016;68(4):498–506. Available from: <http://dx.doi.org/10.1016/j.ihj.2015.10.384>
16. Ahmed HM, Khan M, Yasmin F, Jawaid H, Khalid H, Shigri A, et al. Awareness regarding causes of infertility among out-patients at a tertiary care hospital in Karachi, Pakistan. *Cureus* [Internet]. 2020;12(4):e7685. Available from: <http://dx.doi.org/10.7759/cureus.7685>
17. Agarwal A, Mulgund A, Hamada A, Chyatte MR. A unique view on male infertility around the globe. *Reprod Biol Endocrinol* [Internet]. 2015;13(1):37. Available from: <http://dx.doi.org/10.1186/s12958-015-0032-1>
18. Bui AD, Sharma R, Henkel R, Agarwal A. Reactive oxygen species impact on sperm DNA and its role in male infertility. *Andrologia* [Internet]. 2018;50(8):e13012. Available from: <http://dx.doi.org/10.1111/and.13012>
19. Barati E, Nikzad H, Karimian M. Oxidative stress and male infertility: current knowledge of pathophysiology and role of antioxidant therapy in disease management. *Cell Mol Life Sci* [Internet]. 2020;77(1):93–113. Available from: <http://dx.doi.org/10.1007/s00018-019-03253-8>
20. Kadhem WM, Majhwol EM. Effect some of antiepileptic drugs (AEDs) on some male reproductive parameters in white rats. *EurAsian Journal of BioSciences*. 2020;14(1):1925–8.
21. Ogedengbe OO, Jegede AI, Onanuga IO, Ofor U, Naidu EC, Peter AI, et al. Coconut oil extract mitigates testicular injury following adjuvant treatment with antiretroviral drugs. *Toxicol Res* [Internet]. 2016;32(4):317–25. Available from: <http://dx.doi.org/10.5487/TR.2016.32.4.317>
22. Nayeri Kaman GD, Motiollah F. Phenytoin and the reproductive system. *Medical Journal of The Islamic Republic of Iran (MJIRI)*. 2002;16(1):35–40.
23. Montouris G, Morris GL 3rd. Reproductive and sexual dysfunction in men with epilepsy. *Epilepsy Behav* [Internet]. 2005;7 Suppl 2:S7–14. Available from: <http://dx.doi.org/10.1016/j.yebeh.2005.08.026>
24. Dosumu OO, Akinola OB, Akang EN. Alcohol-induced testicular oxidative stress and cholesterol homeostasis in rats-The therapeutic potential of virgin coconut oil. *Middle East Fertility Society Journal*. 2012;17(2):122–8.
25. Faisal R. Protective Role of Antioxidant Oils in Phenytoin Induced Toxicity of Seminiferous Tubules in Rats. *InMed Forum*. 2021;32(4).