

The Effectiveness of Submucosal Dexamethasone after Third Molar Extraction. A Single Blind Randomized Clinical Trial

Saeed Ullah Shah, Nameera Agha, Abhishek Lal, Rahima Yousofi, Resham Nadeem, Naseer Ahmed

ABSTRACT:

Objective: To evaluate the efficacy of dexamethasone in alleviating pain and trismus of the patients who underwent extraction of the third molars.

Methodology: A total of 120 patients took part in this randomized, controlled trial. The wisdom teeth of patients were surgically extracted under local anesthesia. The patients were randomly assigned to one of two groups and study control with 60 patients in each group. Preoperative and Postoperative measurements of edema, trismus and pain were analyzed. In study group, dexamethasone was immediately given after extraction. However, in control group, no dexamethasone was given to the patients. The paired t-test was carried out to compare the means scores of pains and trismus and. A p value of = 0.05 was judged significant.

Results: The pain scores of patients in group 1 were mostly pain-free on the third post-operative day after dexamethasone administration, with complete pain resolution in all patients on the seventh post-operative day. About trismus in post operative phase almost all of the patients belonging to group 1 did not report to suffer from trismus with just two patients complaining of mild trismus. Whereas, on the 7th post-operative day, all of the group 1 patients free from trismus. About the comparison of trismus, pain and Edema in study groups, a significant difference $p < 0.05$ was found.

Conclusion: Inflammatory complications are frequently associated in the post operative phase of extraction of third molars. Dexamethasone has been proven to be useful in reduction of pain, trismus and edema experienced by the patients when no intervention has been given.

Keywords: Dexamethasone, Dental pain, Exodontia, Edema Postoperative complication, Trismus,

How to cite this Article:

Shah SU, Agha N, Lal A, Yousofi R, Nadeem R, Ahmed N. The Effectiveness of submucosal Dexamethasone after Third Molar Extraction. A Single Blind Randomized Clinical Trial. J Bahria Uni Med Dental Coll. 2022; 12(4):197-201 DOI: <https://doi.org/10.51985/JBUMDC202207>

This is an Open Access article distributed under the terms of the Creative Commons Attribution Non Commercial License (<http://creativecommons.org/licenses/by-nc/4.0>) which permits unrestricted non commercial use, distribution and reproduction in any medium, provided the original work is properly cited.

INTRODUCTION:

The third molar root forms between the ages of 18 and 25, and it is the last tooth to erupt. However, it may continue

Saeed Ullah Shah
Assistant Professor, Department of Oral and Maxillofacial Surgery, Altamash Institute of Dental Medicine, Karachi, Pakistan.

Nameera Agha
Lecturer, Department of Oral Surgery, Ziauddin University, Karachi, Pakistan

Abhishek Lal
House Surgeon, Department of Prosthodontics, Altamash Institute of Dental Medicine, Karachi, Pakistan.

Rahima Yousofi
Lecturer, Research and Development Cell, Altamash Institute of Dental Medicine, Karachi, Pakistan

Resham Nadeem
Lecturer, Department of Prosthodontics, Altamash Institute of Dental Medicine, Karachi, Pakistan.

Naseer Ahmed (Corresponding Author)
Associate Professor, Department of Prosthodontics, Altamash Institute of Dental Medicine, Karachi, Pakistan. Email: naprosthodontist@gmail.com

Received: 10-Jan-2022
Accepted: 16-Sep-2022

to erupt even after the age of 25. The most common dentoalveolar procedure in oral and maxillofacial surgery is the removal of maxillary and mandibular third molars. Impaction being the most common reason and surgical procedure for removal of the third molar and is also associated with various postoperative complications such as permanent nerve damage. Because impacted mandibular third molars are near to inferior alveolar vessels, surgical procedures to this highly vascular area result in exudate liberation, causing significant edema, discomfort, and trismus in the days following surgery and serious infection are the most severe complication of following molar extraction.¹ The factors contributing to these postoperative difficulties are related to the inflammatory process. Inflammatory symptoms differ from patient to patient in occurrence and its severity. Other causes include pericoronitis, cystic lesions, neoplasms, pathological, and root resorption which can cause detrimental effects on the tooth associated along with the neighboring teeth.^{2,3}

Corticosteroids have been used at different dosages to lessen the inflammatory effects of third molar surgical removal.⁴ Corticosteroids are available of its potential anti-inflammatory effects, dexamethasone is useful in decreasing pain and is

currently the most dominant anti-inflammatory drug, with a long half-life.⁵ Administered through intravenous or intramuscular route, betamethasone, dexamethasone, and methylprednisolone, are the most widely used corticosteroids.⁶

For the patients the administration of dexamethasone for the reduction of pain, trismus. However, duration and dosage should be kept in mind as prolonged use of corticosteroids can delay in the healing process and increase the patient's susceptibility to infections.⁷

A single glucocorticoid dose inhibits the synthesis and/or release of pro-inflammatory and inflammatory mediators in a variety of surgical procedures, with a reduction of fluid transudation and therefore edema.^{8,9} In order to evaluate the use of dexamethasone to alleviate pain and trismus in patients undergoing extraction of third molars, various clinical trials have been carried out. They were given 4 mg of dexamethasone and postoperative pain was evaluated using a visual analog scale (VAS) and the degree of swelling was evaluated through facial reference points' variation. These assessments were obtained before the operation and after the surgery. The usefulness of dexamethasone in the reduction of pain and trismus has been reported in various clinical trials in the literature.^{10,11}

Since the development of pain and trismus in patients who have undergone extraction of third molars can be proven to be troublesome for the patients, interventions are required to relieve the patients of such inflammatory complications. In this study, we aimed to evaluate the efficacy of dexamethasone in alleviating pain, trismus and edema of the patients who underwent extraction of the third molars.

METHODOLOGY:

In this study, the ethical approval was granted from the ethics and review committee of Altamash Institute of Dental Medicine, Pakistan (reference code: AIDM/ERC/07/2021/01). This study was conducted in accordance with the Declaration of Helsinki. The participants for this study were recruited using a convenience sample method.

In this randomized controlled trial, a total of 120 patients participated in which the bony impacted teeth (Third Molar) were surgically extracted under local anesthesia, after effectiveness of local anesthesia incision was given raised the mucosal periosteal flap expose the bone at buccal surface of teeth and buccal guttering of bone done to make a purchase point and then teeth section accordingly for ease of extraction. The patients who were diagnosed and advised surgical extraction of the third molars under local anesthesia with no co-morbidities were included in this study. Patients who had pericoronitis/infection at the time of surgery were unable to give informed consent, knew they had a hypersensitivity or allergic reaction to corticosteroids and had a recent history of taking anti-inflammatory, antibiotic, or narcotic drugs, lactating and smokers were excluded from the study. All the patients were selected from the Department of Oral and

Maxillofacial Surgery, Altamash Institute of Dental medicine and to ensure voluntary participation, written informed consent was obtained from all participants after they were given full written and verbal information of the trial for publication of the study findings. The data that was collected from the participants was kept confidential throughout the study.

The patients were randomly divided into two groups, the Study group and Control with 60 patients in each group and the duration of the study were 6 months.

In the study group, each patient had rinsed with 5ml chlorhexidine mouth wash for a minute and the lingual nerve were blocked with local anesthesia (lidocaine 2% & epinephrine 1:10,000) to proceed with the extraction after the procedure a dexamethasone with the dose of 4mg was immediately given to the patient buccally to the third molar extraction site as a submucosal injection. Post-operatively all the patients were prescribed with antibiotics and painkillers. However, in the control group, each patient had rinsed with 5ml chlorhexidine mouth wash for a minute and the lingual nerve were blocked with local anesthesia (lidocaine 2% & epinephrine 1:10,000) to proceed with the extraction after the procedure no dexamethasone was given to the group of patients. A toss and coin technique were used to divide patients into these groups, figure 1. It was a single-blinded technique.

All the standard surgical and aseptic measures were strictly followed. The surgeons who performed the surgery followed personal protective equipment to ensure aseptic measures.

The trismus, swelling and pain sequelae were assessed on the 3rd and 7th day of the extraction. The trismus were evaluated by using Varnier caliper scale with reference point of inter incisal distance less than 35mm interincisal distance consider trismus. swelling was measured by drawing two imaginary line one from outer cantus of eye into antionion notch of mandible, 2nd line draw from tragus of ear to ala of the nose the interacting of two line make triangle through which we measure the swelling and pain was assess by using visual analog scale 1-3 mild, 4-6 moderate, 7-10 severe.

For data analysis of this study, we used Statistical Package for Social Sciences (SPSS) version 25. The descriptive analysis was carried out to calculate the percentage, mean and standard deviation of age, gender, type of impaction, pain, and trismus scores. The paired T-test was carried out to compare the means scores of pains and trismus in between the study group and control group. A p-value of =0.05 was considered to be as statistically significant.

RESULTS:

In this randomized controlled trial, we recruited a total of 120 patients. The patients were then randomized into 2 groups: Group 1 was administered Dexamethasone and Group 2 was control. The mean age of patients in the two

groups is as follows: Group 1: 28.55 ± 4.48 and Group 2: 29.28 ± 4.00 . About gender, the distribution of males and females in each of the groups is as follows: Group 1: 24 and 36, and Group 2: 16 and 44. Regarding smoking, there were 17 smokers in group 1 and 9 smokers in group 2. The distribution of the type of impaction is presented in table 1. About the pain scores of patients in group 1, most of the patients were pain free on the 3rd post operative day after the administration of dexamethasone, with complete resolution of pain in all of the patients on the 7th post operative day. However, patients in group 2 did experience mild pain, with some patients suffering from moderate and severe pain. Furthermore, most of the patients in group 2 on the 7th post operative day were pain free. About comparison of pain scores between the two groups, a significant difference was found (p -value=0.001) as presented in table 2. About trismus in post operative phase almost all of the patients belonging to group 1 did not report to suffer from trismus with just two patients complaining of mild trismus. On the 7th post operative day, all of the group 1 patients free from trismus. However, majority of the patients of group 2 did not complaint of trismus, but few did complaint of experience mild to moderate trismus on the 3rd post operative day. Furthermore, on the 7th post operative day, patients belonging to group 2 did not experience any trismus. About the comparison of trismus amongst the patients, a significant difference was found (p -value= 0.004), as presented in table 3.

DISCUSSION:

The third molar teeth are the last to erupt with a relatively high chance of becoming impacted. Many causes are associated that requires the extraction of the third molars that includes impaction being the most frequent complaint of the patient and the surgical extraction of many impacted mandibular third molars which have been asymptomatic for years are often carried out to prevent the development of any future complications and pathologic conditions followed by caries, periodontitis and trauma. The third molars can be extracted either non-surgically or surgically, which varies from patient to patient. Complications associated with the removal of impacted teeth are relevant and are aided by local and general factors which include tooth position, age

Figure 1: Consort flow diagram of the study

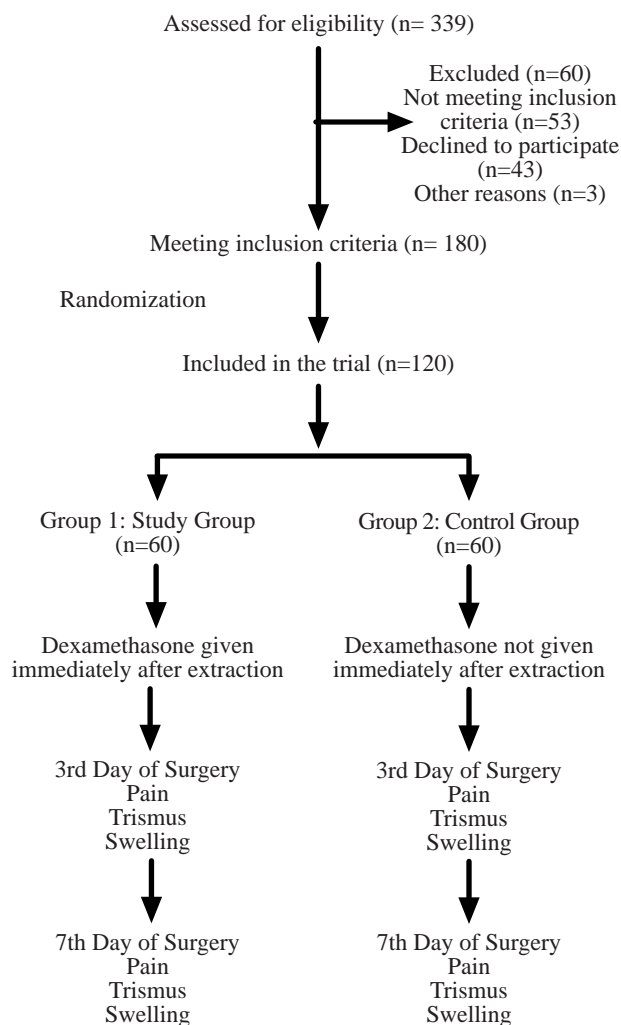


Table 1. Type of Impaction of Third Molar in the patients

Groups	Type of Impaction			
	Horizontal	Vertical	Mesioangular	Distoangular
Group 1	16 (26.66%)	11 (18.33%)	21 (12.25%)	12 (20%)
Group 2	14 (23.33%)	15 (25%)	17 (28.33%)	14 (23.33%)

Table 2. Comparison of pain scores in the patients (n=120)

Groups		Mean	N	Std. Deviation	Std. Error Mean	T	df	p-value
Study and Control groups	Group 1	3.85	60	0.659	0.085	5.958	59	0.001
	Group 2	3.06	60	0.936	0.120			

Table 3: Comparison of trismus in the patients

Groups		Mean	N	Std. Deviation	Std. Error Mean	T	df	p-value
Study and Control groups	Group 1	3.85	60	0.661	0.085	3.037	59	0.004
	Group 2	3.55	60	0.804	0.102			

of the patient, health status, knowledge and experience of the dental surgeon, and surgical equipment used. Complications associated with the removal of the third molar include damage of the sensory nerve leading to paresthesia, dry socket, infection, severe trismus, oro-antral fistula, buccal fat herniations. About surgical extraction of the third molars, pain and trismus is a frequent complaint experienced by the patients.

Glucocorticoids are known to have an anti-inflammatory that is documented well in the literature with the purposed mechanism that involves the suppression of accumulation of leucocytes and macrophages at the site of inflammation and preventing the formation of prostaglandins.¹² Corticosteroids act by suppressing each phase of the initial inflammatory response, thereby decreasing cellular permeability and capillary dilatation by inhibiting the production of vasoactive substances and diminishing the amount of cytokines. Furthermore, the generation of prostaglandin is repressed by corticosteroids, resulting in an analgesic effect. Corticosteroids have been proven to be useful in reducing pain and swelling experienced by the patients regardless of the route of administration. Dexamethasone is a corticosteroid, that is given as orally, intravenously, intramuscularly, and submucosal either in preoperative or post-operative phase.^{13,14,7}

In this study, patients in group 1 were assigned to intra oral injections of administration of dexamethasone. On the 3rd post-operative day, most of the patients who were given dexamethasone were pain free with complete resolution of pain in the remaining patients on the 7th post operative day. These results correspond to various studies in the literature that concludes dexamethasone to alleviate pain after patients underwent extraction of the third molars.^{15,5}

Trismus is a condition that is defined as limitation of mouth opening, a decrease in maximum interincisal opening that is a consequence due to edema, swelling, and pain cause by patient undergoing a surgical procedure. In this study, when comparison was done amongst the groups with respect to post-operative trismus, the results were found to be statistically significant. The patients who were assigned to dexamethasone, majority of the patients did not complaint of suffering limitation of mouth opening, with complete resolution of trismus on the 7th post operative day. These findings have also been reported in the studies in the literature that found dexamethasone to be useful in preventing trismus in patients who underwent third molar extractions.^{16,17}

About the patients who were not assigned to any intervention in the post operative phase of the third molar extraction, these patients did experience mild to moderate levels of pain and trismus. These results correspond with a study by Ngeow et al that reported higher level of pain scores in patients that were not assigned to any pain reduction intervention¹⁸. However, a study by Grossi et al found no difference between

the control and dexamethasone groups in reduction of pain scores, swelling, and trismus.¹⁹

Smoking is known to interfere with the healing process after third molar extraction. Most of the times, the patients are instructed to discontinue smoking for a certain period of time. Smoking may disrupt the formation of blood clot in the socket and hinder the normal healing process of the socket, that eventually delay the healing of the socket.²⁰ Moreover, smoking also has an effect on the levels of pain as smokers tend to experience greater levels of postoperative extraction pain as compared to the non-smokers.²¹

Different studies have been carried to evaluate its effectiveness in controlling pain, trismus and swelling. Studies do suggest that dexamethasone is effective in reducing pain, swelling, and trismus complaint of the patients.²² Moreover, in a study by Latt et al, it was concluded that dexamethasone injection in the pterygomandibular space effectively reduced the postoperative pain and its sequelae after lower mandibular third molar extractions.²³

As the inflammation progress the interstitial fluid accumulation due to transudation from injured blood vessels and obstruction of lymphatic drainage by fibrin and fibrinogen clots derived from plasma and adjacent injured vessels leads to postoperative edema complications experienced by the patients in the post operative phase of third molar extractions is a bothersome experience for the patients that mandates intervention for its resolution. Despite the strengths of this study such as inclusion of large sample size of the patients, and regular follow up of the patients, we were met with some limitation. Firstly, compliance of the patients with the drugs might be a factor that might affect the results of this study. Lastly, patients were advised for temporary cessation of smoking which the patients might not have followed.

CONCLUSION:

The post operative phase complications are frequently associated with the extraction of third molars. Dexamethasone has been proven to be useful in reduction of pain, swelling and trismus experienced by the patients when no intervention has been given. Thus, we recommend the submucosal administration of dexamethasone, as an easier and more comfortable route of administration which showed significant difference in reduction in pain, swelling and trismus, and on entire assessment it was found superior for the improvement of postoperative quality of life of patient.

Authors Contribution:

Saeed Ullah Shah: Conceived and designed
Nameera Agha: Collected data
Abhishek Lal: Analysis
Rahima: Interpretation of Data
Resham Nadeem: Wrote the paper
Naseer Ahmed: Performed the Analysis

REFERENCES:

1. Santosh P. Impacted mandibular third molars: Review of literature and a proposal of a combined clinical and radiological classification. *Ann Med Health Sci Res* [Internet]. 2015; 5(4):229. <https://doi.org/10.4103/2141-9248.160177>
2. Patil S, Halgatti V, Khandelwal S, Santosh BS, Maheshwari S. Prevalence of cysts and tumors around the retained and unerupted third molars in the Indian population. *J Oral Biol Craniofacial Res* [Internet]. 2014 ;4(2):82–7. Available from: <https://linkinghub.elsevier.com/retrieve/pii/S2212426814000335>
3. Mello FW, Melo G, Kammer PV, Speight PM, Rivero ERC. Prevalence of odontogenic cysts and tumors associated with impacted third molars: A systematic review and meta-analysis. *J Cranio-Maxillofacial Surg* [Internet]. 2019 Jun;47(6): 9961002. <https://doi.org/10.1016/j.jcms.2019.03.026>
4. Sugragan C, Sirintawat N, Kiattavornchareon S, Khoo LK, KC K, Wongsirichat N. Do corticosteroids reduce postoperative pain following third molar intervention? *J Dent Anesth Pain Med* [Internet]. 2020;20(5):281. <https://jdapm.org/DOIx.php?id=10.17245/jdapm.2020.20.5.281>
5. O'Hare PE, Wilson BJ, Loga MG, Ariyawardana A. Effect of submucosal dexamethasone injections in the prevention of postoperative pain, trismus, and oedema associated with mandibular third molar surgery: a systematic review and meta-analysis. *International journal of oral and maxillofacial surgery*. 2019;48(11):1456-69
6. Hodgens A, Sharman T. Corticosteroids [Internet]. *StatPearls*. 2021. Available from: [. nih.gov/ pubmed/ 32119499](http://pubmed.ncbi.nlm.nih.gov/pubmed/32119499)
7. Arora SS, Phull T, Kumar I, Kumar A, Kumar N, Singh H. A comparative study of the effect of two dosages of submucosal injection of dexamethasone on postoperative discomfort after third molar surgery: a prospective randomized study. *Oral and maxillofacial surgery*. 2018 Jun;22(2):225-30.
8. Coutinho AE, Chapman KE. The anti-inflammatory and immunosuppressive effects of glucocorticoids, recent developments and mechanistic insights. *Mol Cell Endocrinol* [Internet]. 2011 ;335(1):2–13. <https://doi.org/10.1016/j.mce.2010.04.005>
9. Yasir M, Goyal A, Bansal P, Sonthalia S. Corticosteroid Adverse Effects [Internet]. *StatPearls*. 2021. Available from: <http://www.ncbi.nlm.nih.gov/pubmed/30285357>
10. Sreesh S, Ummar M, Sooraj S, Aslam S, Roshni A, Jabir K. Postoperative pain, edema and trismus following third molar surgery – A comparative study between submucosal and intravenous dexamethasone. *J Fam Med Prim Care* [Internet]. 2020;9(5):2454. Available from: https://journals.lww.com/jfmpc/Fulltext/2020/09050/Postoperative_pain_edema_and_trismus_following.57.aspx
11. Bamgbose BO, Akinwande JA, Adeyemo WL, Ladeinde AL, Arotiba GT, Ogunlewe MO. Effects of co-administered dexamethasone and diclofenac potassium on pain, swelling and trismus following third molar surgery. *Head Face Med* [Internet]. 2005 ;1(1):11. Available from: <https://head-face-med.biomedcentral.com/articles/10.1186/1746-160X-1-11>
12. Ricciotti E, FitzGerald GA. Prostaglandins and Inflammation. *Arterioscler Thromb Vasc Biol* [Internet]. 2011 ;31(5):986–1000. <https://doi.org/10.1161/ATVBAHA.110.207449>
13. Antunes AA, Avelar RL, Martins Neto EC, Frota R, Dias E. Effect of two routes of administration of dexamethasone on pain, edema, and trismus in impacted lower third molar surgery. *Oral Maxillofac Surg* [Internet]. 2011 ;15(4):217–23. Available from: <http://link.springer.com/10.1007/s10006-011-0290-9>
14. Gholami M, Anbiaee N, Abad SB, Asadi M. What Are the Effects of Methylprednisolone Injection Into the Masseter and Gluteal Muscle on Pain, Edema, and Trismus After Impacted Lower Third Molar Surgery? A Randomized Clinical Trial. *Journal of Oral and Maxillofacial Surgery*. 2021 Sep 1;79(9):1829-36.
15. Falci SGM, Lima TC, Martins CC, Santos CRR dos, Pinheiro MLP. Preemptive Effect of Dexamethasone in Third-Molar Surgery: A Meta-Analysis. *Anesth Prog* [Internet]. 2017 Sep 1;64(3):136–43. <https://doi.org/10.2344/anpr-64-05-08>
16. Lima CAA, Favarini VT, Torres AM, da Silva RA, Sato FRL. Oral dexamethasone decreases postoperative pain, swelling, and trismus more than diclofenac following third molar removal: a randomized controlled clinical trial. *Oral Maxillofac Surg* [Internet]. 2017;21(3):321–6. Available from: <http://link.springer.com/10.1007/s10006-017-0635-0>
17. Sabhlok S. Randomized Controlled Trial to Evaluate the Efficacy of Oral Dexamethasone and Intramuscular Dexamethasone in Mandibular Third Molar Surgeries. *J Clin DIAGNOSTIC Res* [Internet]. 2015;DOI: 10.7860/JCDR/2015/13930.6813
18. Ngeow WC, Lim D. Do Corticosteroids Still Have a Role in the Management of Third Molar Surgery? *Adv Ther* [Internet]. 2016;33(7):1105–39. Available from: <http://link.springer.com/10.1007/s12325-016-0357-y>
19. Grossi GB, Maiorana C, Garramone RA, Borronovo A, Beretta M, Farronato D, et al. Effect of Submucosal Injection of Dexamethasone on Postoperative Discomfort After Third Molar Surgery: A Prospective Study. *J Oral Maxillofac Surg* [Internet]. 2007;65(11):2218–26. Available from: <https://linkinghub.elsevier.com/retrieve/pii/S0278239106022051>
20. Sanari AA, Alsolami BA, Abdel-Alim HM, Al-Ghamdi MY, Meisha DE. Effect of smoking on patient-reported postoperative complications following minor oral surgical procedures. *Saudi Dent J* [Internet]. 2020;32(7):357–63. Available from: <https://linkinghub.elsevier.com/retrieve/pii/S1013905219306339>
21. Al-Delayme RM. The effect of cigarette smoking on the severity of pain, swelling and trismus after the surgical extraction of impacted mandibular third molar. *J Clin Exp Dent*. 2013;5(3):e117-21. DOI: 10.4317/jced.50979
22. Falci SGM, Lima TC, Martins CC, Santos CRR dos, Pinheiro MLP. Preemptive Effect of Dexamethasone in Third-Molar Surgery: A Meta-Analysis. *Anesth Prog* [Internet]. 2017 ;64(3):136–43. Available from: <https://meridian.allenpress.com/anesthesia-progress/article/64/3/136/25009/Preemptive-Effect-of-Dexamethasone-in-ThirdMolar>
23. Latt MM, Kiattavornchareon S, Boonsiriset K, Pairuchvej V, Wongsirichat N. The efficacy of dexamethasone injection on postoperative pain in lower third molar surgery. *J Dent Anesth Pain Med* [Internet]. 2016;16(2):95. Available from: <https://jdapm.org/DOIx.php?id=10.17245/jdapm.2016.16.2.95>

